

AUSTRALIAN ORTHOPTIC JOURNAL - 2013 VOLUME 45

- 04 **Editorial - Orthoptics at the Crossroads: Matching Future Workforce Needs**  
Jane Scheetz, Konstandina Koklanis, Maureen Long, Meg Morris
- 06 **The Relationship between the Clinical Assessment Temporal Artery Biopsy and the Positive Diagnosis of Giant Cell Arteritis**  
Natalie Duffy
- 10 **A Case Study and Literature Review of Coexisting Dissociated Vertical and Horizontal Deviations**  
Cassandra Norris, Linda Santamaria
- 15 **The Multidisciplinary Glaucoma Monitoring Clinic at The Royal Victorian Eye and Ear Hospital**  
Debra Gleeson
- 19 **A Case Report: Complicated Traumatic Hyphaema**  
Khoi Khuat, Elaina Dickeson
- 24 **Charles Bonnet Visual Hallucinations in Children: A Systematic Review**  
Meri Vukicevic, Stuart Keel
- 28 **Selected Abstracts from the Orthoptics Australia 70th Annual Scientific Conference held in Hobart 3 to 6 November 2013**
- 33 **Named Lectures, Prizes and Awards of Orthoptics Australia**
- 35 **Presidents of Orthoptics Australia and Editors of the Australian Orthoptic Journal**
- 36 **Orthoptics Australia Office Bearers, State Branches & University Training Programs**

Orthoptics at the  
Crossroads

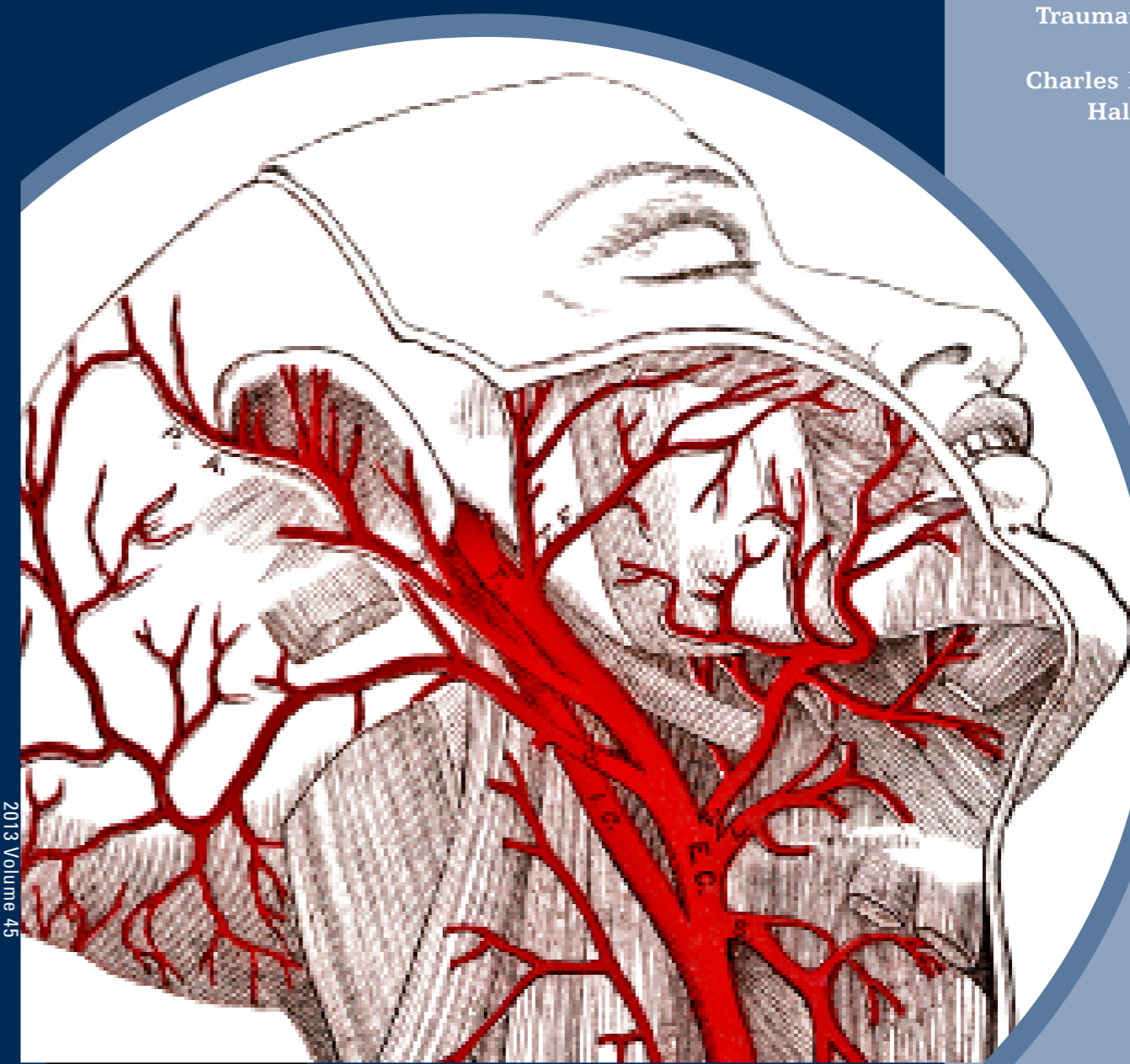Diagnosis of Giant  
Cell Arteritis

Coexisting Dissociated  
Vertical and Horizontal  
Deviations

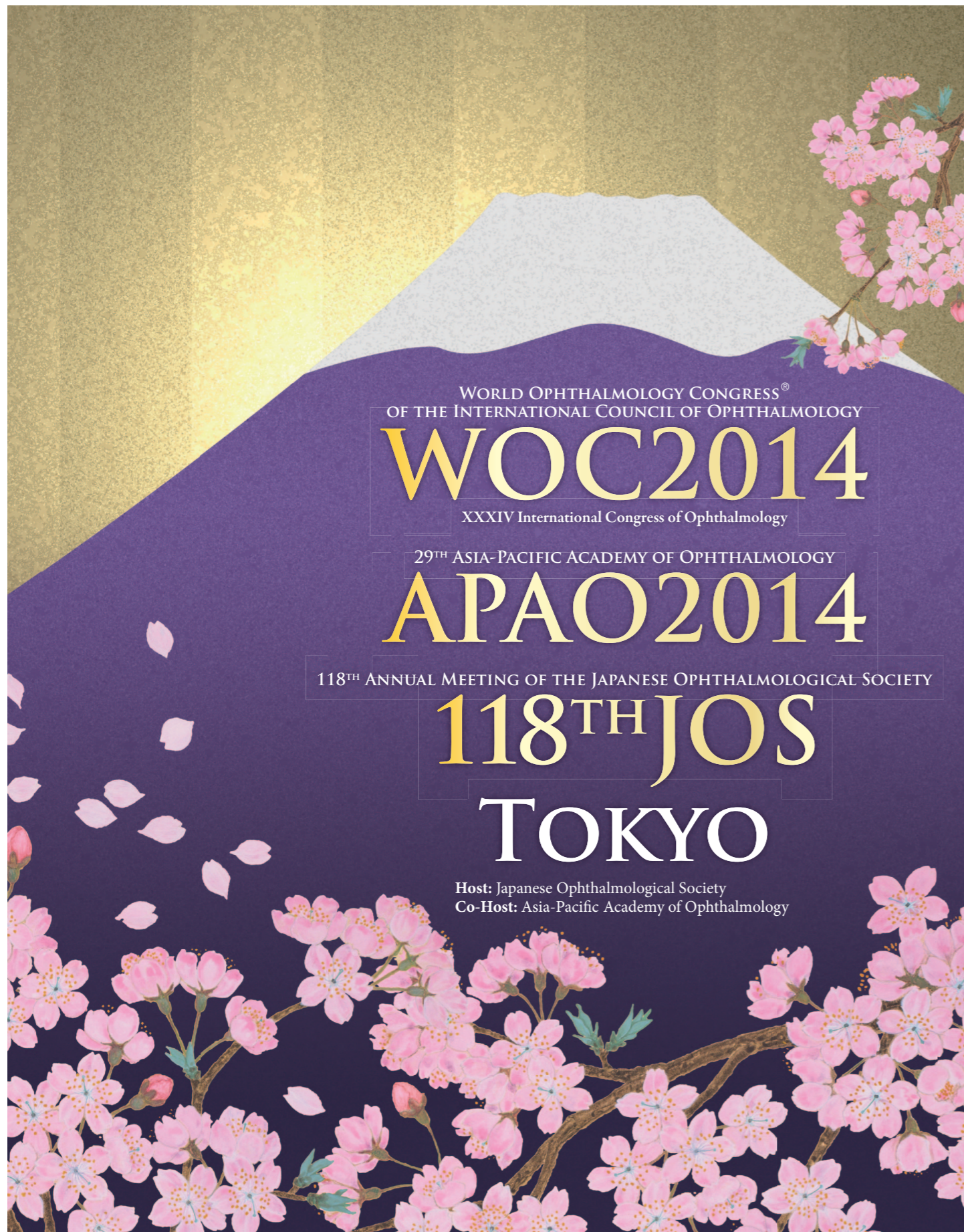Multidisciplinary  
Glaucoma  
Monitoring Clinic

Traumatic Hyphaema

Charles Bonnet Visual  
Hallucinations in  
Children







**April 2 – 6, 2014** Venue: Tokyo International Forum / Imperial Hotel, Tokyo

**President** Tetsuro Oshika, M.D., *President, WOC2014/118th JOS*  
Makoto Araie, M.D., *President, APAO2014*



Secretariat: c/o Congress Corporation  
Kōsai-kaikan Bldg., 5-1 Kojimachi, Chiyoda-ku, Tokyo 102-8481, Japan  
Phone: +81-3-5216-5551 Fax: +81-3-5216-5552 E-mail: woc2014tokyo@congre.co.jp

[www.woc2014.org](http://www.woc2014.org)



# ANNUAL MEETING

The Royal Australian and New Zealand  
Strabismus Society

Friday 7th and Saturday 8th March 2014

The Royal Automobile Club of Australia  
89 Macquarie Street Sydney

## GUEST SPEAKERS

Professor David Granet M.D., F.A.C.S., F.A.A.P.

Director of the Division of Paediatric Ophthalmology and Eye Alignment Disorders for the University of California, San Diego and Professor of Ophthalmology and Paediatrics at UCSD. Also the adult ocular motility specialist for the Shiley Eye Centre

Cheryl McCarus, BS, CO, COMT

President of the American Association of Certified Orthoptists, Director Department of Ophthalmology, Greater Baltimore Medical Centre

## CALL FOR ABSTRACTS:

Please send all abstracts to Craig Donaldson at [craigdonaldson@msn.com.au](mailto:craigdonaldson@msn.com.au) by 7 February 2014.





---

# Australian Orthoptic Journal

2013 Volume 45

The official journal of Orthoptics Australia  
ISSN 0814-0936

## Editors in Chief

Konstandina Koklanis BOrth(Hons) PhD  
Linda Santamaria DipAppSc(Orth) MAppSc

---

### Editorial Board

Kyle Arnoldi CO COMT (Buffalo NY)  
Carolyn Calcutt DBO(D) (London, England)  
Jill Carlton MMedSci(Orth), BMedSci(Orth)  
Nathan Clunas BAppSc(Orth)Hons PhD  
Elaine Cornell DOBA DipAppSc MA PhD  
Catherine Devereux DipAppSc(Orth) MAppSc  
Kerry Fitzmaurice HTDS DipAppSc(Orth) PhD  
Mara Giribaldi BAppSc(Orth)  
Julie Green DipAppSc(Orth) PhD

Neryla Jolly DOBA(T) MA  
Linda Malesic BOrth(Hons) PhD  
Karen McMain BA OC(C) COMT (Halifax, Nova Scotia)  
Jean Pollock DipAppSc(Orth) GradDip(Neuroscience) MSc  
Gill Roper-Hall DBOT CO COMT  
Kathryn Rose DOBA DipAppSc(Orth) GradDip(Neuroscience) PhD  
Sue Silveira DipAppSc(Orth) MHLthScEd  
Kathryn Thompson DipAppSc(Orth) GradCertHlthScEd MAppSc(Orth)  
Suzane Vassallo BOrth(Hons) PhD  
Meri Vukicevic BOrth PGDipHlthResMeth PhD  
Liane Wilcox DOBA MAppSc

---

The Australian Orthoptic Journal is peer-reviewed and the official biannual scientific journal of Orthoptics Australia. The Australian Orthoptic Journal features original scientific research papers, reviews and perspectives, case studies, invited editorials, letters and book reviews. The Australian Orthoptic Journal covers key areas of orthoptic clinical practice – strabismus, amblyopia, ocular motility and binocular vision anomalies; low vision and rehabilitation; paediatric ophthalmology; neuro-ophthalmology including nystagmus; ophthalmic technology and biometry; and public health agenda.

Published by Orthoptics Australia (Publication date: January 2014).

Editor's details: Konstandina Koklanis, k.koklanis@latrobe.edu.au; Department of Clinical Vision Sciences, La Trobe University. Fax: +61 3 9479 3692. Linda Santamaria, linda.santamaria@monash.edu; Department of Surgery, Monash University. Email: AOJ@orthoptics.org.au. Design & layout: Campus Graphics, La Trobe University. Printer: Printing Edge Melbourne Pty Ltd. Publisher: Orthoptics Australia (PO Box 1104, Greythorn, VIC 3104 Australia).

All rights reserved. Except as permitted by the Copyright Act 1968, pursuant to a copying licence you may have with the reproduction rights organisation Copyright Agency Limited ([www.copyright.com.au](http://www.copyright.com.au)) or if the use is for personal use only, no part of this publication may be reproduced, stored in a retrieval system, communicated or transmitted in any form or by any means; electronic, mechanical, photocopying, recording or otherwise; without prior permission of the copyright owners. By publishing in the Australian Orthoptic Journal, authors have conferred copyright ownership to Orthoptics Australia, Copyright 2013 © Orthoptics Australia 2013. All rights reserved.



## Advertising in the Australian Orthoptic Journal

For information on advertising, please contact our Advertising & Sponsorship Manager, Karen Mill: [k.mill@orthoptics.org.au](mailto:k.mill@orthoptics.org.au) or [AOJ@orthoptics.org.au](mailto:AOJ@orthoptics.org.au)

Advertisements can be full page (210 x 297 mm, plus bleed), half page (186 x 135.5 mm) or quarter page (90 x 135.5 mm).

---

## GUIDELINES FOR AUTHORS

---

It is a condition of acceptance of any article for the Australian Orthoptic Journal that original material is submitted. The cover letter accompanying the submission must state that the manuscript has not been published or submitted for consideration for publication elsewhere.

The types of manuscripts accepted are as follows:

- (i) Editorials (by invitation)
- (ii) Original Scientific Research Papers
- (iii) Reviews/Perspectives
- (iv) Case Studies
- (v) Letters to the Editor
- (vi) Book Reviews.

## MANUSCRIPT SUBMISSION

---

Submitted manuscripts must include a cover letter, title page, abstract (including keywords), the paper itself, any acknowledgements, references and tables and/or figures. Each of these sections should begin on a separate page. Pages should be sequentially numbered. The manuscript submission should be electronic, via email to: AOJ@orthoptics.org.au

**Cover Letter:** The cover letter must include information regarding ethical considerations, informed consent and potential conflicts of interest, in addition to the statement regarding the originality of the manuscript.

*Ethical Considerations:* Authors must state that the protocol for any research project has been approved by an appropriate Ethics Committee that conforms to the provisions of the Declaration of Helsinki in 1995 (as revised in Edinburgh 2000). Investigators who do not have a formal ethics review committee must indicate they have adhered to the aforementioned provisions.

*Informed Consent:* Research on human subjects must include a statement that the subject provided informed consent and investigators must ensure patient confidentiality. Animal experiments must be demonstrated to be ethically acceptable and where relevant conform to institutional and national guidelines for the care and use of animals in research.

*Conflict of Interest:* Authors must declare any financial support or relationships that may, or may be perceived to, pose a conflict of interest. If there is none this should be stated.

**Title Page:** The title page should include the title of the manuscript and each author's name, academic qualifications and institutional affiliation(s). A 'corresponding author' should be designated and their address, telephone number, fax number, and email address listed. The title page should also include the word count for the abstract and text.

**Abstract and Keywords:** The abstract should not exceed 250 words. It should be a clear and succinct summary of the paper presented and need not be structured into subsections. However, where appropriate, it should relate to the format of the paper, including aim, methods, results and conclusion. Beneath the abstract, include up to five keywords or terms suitable for use in an index or search engine.

**Text:** Manuscripts should not exceed 3,000 words. Where appropriate the structure of the text should be as follows: Introduction, Method, Results, Discussion and Conclusion. For scientific research the methods section of the manuscript should also address ethical considerations and informed consent. Authors should also use subheadings for Case Studies, generally as follows: Introduction, Case Report and Discussion (Conclusion is optional). Case Studies should not exceed 1,500 words.

**References:** References must be numbered consecutively in order of appearance in the text. In-text references should be designated a superscript number following all punctuation. When there are five or more authors, only the first three should be listed followed by et al. References to journal articles should conform to abbreviations in Index Medicus. Examples of reference styles are as follows:

**Article:** Wilson ME, Eustis HS, Parks MM. Brown's Syndrome. *Surv Ophthalmol* 1989;34(3):153-172.

**Book:** Kline LB, Bajandas FJ. *Neuro-ophthalmology: Review Manual*. 5th Ed. Thorofare: Slack Inc; 2004.

**Book Chapter:** Murphee AL, Christensen LE. Retinoblastoma and malignant tumors. In: Wright KW, Spiegel PH, editors. *Pediatric Ophthalmology and Strabismus*. 2nd Ed. New York: Springer; 2003. p. 584-589.

**Web Page:** Cancer Council Australia. Position statement: eye protection; 2006 [Updated Aug 2008, cited 2010 31st Jul] Available from: <http://www.cancer.org.au/policy/positionstatements/sunsmart/eyeprotection.htm>.

**Tables and Figures:** Tables and figures must be accompanied by a suitable title and numbered consecutively as mentioned in the text. It is preferable if images are supplied as high resolution jpeg, tiff or EPS files.

**Acknowledgements:** Identify all sources of financial support including grants or sponsorship from agencies or companies. Include any acknowledgements to individuals who do not qualify for authorship.

## THE REVIEW PROCESS

---

Manuscripts are reviewed by two referees. The referees are masked to the authors and vice versa. Authors will be notified of the decision once the reviews have been received. Where revisions are required, the author must re-submit within twelve weeks or an agreed timeframe. Revised papers received late will be treated as new submissions.

## ENQUIRIES

---

If you have any enquiries contact the Editors.  
 Email: AOJ@orthoptics.org.au  
 Tel: Dr Connie Koklanis 03 9479 1903  
 Fax: 03 9479 3692  
 Ms Linda Santamaria 03 9594 5502

---

---

# Australian Orthoptic Journal

2013 Volume 45



---

## CONTENTS


---

- 04 Editorial - Orthoptics at the Crossroads: Matching Future Workforce Needs**  
Jane Scheetz, Konstandina Koklanis, Maureen Long, Meg Morris
- 06 The Relationship between the Clinical Assessment, Temporal Artery Biopsy and the Positive Diagnosis of Giant Cell Arteritis**  
Natalie Duffy
- 10 A Case Study and Literature Review of Coexisting Dissociated Vertical and Horizontal Deviations**  
Cassandra Norris, Linda Santamaria
- 15 The Multidisciplinary Glaucoma Monitoring Clinic at The Royal Victorian Eye and Ear Hospital**  
Debra Gleeson
- 19 A Case Report: Complicated Traumatic Hyphaema**  
Khoi Khuat, Elaina Dickeson
- 24 Charles Bonnet Visual Hallucinations in Children: A Systematic Review**  
Meri Vukicevic, Stuart Keel
- 28 Selected Abstracts from the Orthoptics Australia 70th Annual Scientific Conference held in Hobart 3 to 6 November 2013**
- 33 Named Lectures, Prizes and Awards of Orthoptics Australia**
- 35 Presidents of Orthoptics Australia and Editors of the Australian Orthoptic Journal**
- 36 Orthoptics Australia Office Bearers, State Branches & University Training Programs**
-

## Editorial

### Orthoptics at the Crossroads: Matching Future Workforce Needs

Orthoptics is a relatively young discipline, compared to many allied health professions. It originated in London in 1928 with the first ever orthoptist being Mary Maddox who was trained by her father, ophthalmologist Ernest Maddox.<sup>1</sup> In Australia, the training of orthoptists began in 1931 at the Alfred Hospital in Melbourne and by 1990 a bachelor level degree was conferred within the university sector in Victoria. Australia was the first country to offer a bachelor degree in orthoptics and is now well regarded as having the highest educational standards for orthoptists on an international basis. Figure 1 shows the advancement of the delivery of orthoptic education within Victoria, Australia.



**Figure 1.** Timeline of orthoptic education in Victoria, Australia  
(L Santamaria, personal communication, May 30, 2013).

The Australian orthoptic profession has also experienced several academic milestones in the last few decades, with Elaine Cornell being appointed as the first Associate Professor of Orthoptics in 1991 at the Cumberland College of Health Sciences at the University of Sydney<sup>2</sup> and Dr Julie Green being awarded the first Doctor of Philosophy (PhD) at La Trobe University in 1994 (J Pollock, personal communication, June 6, 2013).

Whilst the Australian programs in orthoptics have undergone significant reforms it is noteworthy that the delivery of orthoptic education varies widely across the world. Some countries continue to offer hospital-based training courses whilst others offer bachelor or master level programs within the university sector. In Australia, orthoptists receive training in a wide range of clinical skills which enables them to practise not only in the traditional areas of orthoptics such as ocular motility but also within the field of general ophthalmology.

When the orthoptic profession initially commenced, orthoptists were primarily involved in the diagnosis and management of eye movement disorders such as strabismus and amblyopia. More recently, in the last few decades, the role has expanded into diagnostics within general

ophthalmology and the screening and monitoring of stable low-acuity eye disease. This includes the diagnosis and management of patients with the five major eye disorders causing vision impairment including glaucoma, age-related macular degeneration, diabetic retinopathy, cataract and refractive error.<sup>3</sup> For instance, it is common for orthoptists in Australia to assess cataract patients and determine the intraocular lens required for surgical implantation. This breadth of clinical expertise sets Australian orthoptists apart from some international graduates where training focuses primarily on ocular motility and to a lesser degree general ophthalmic support services.

The need for additional general ophthalmic support services within Australia is becoming more prevalent as our population continues to age. Whilst Australia has one of the best performing health systems in the world, over recent years our Government has progressed health reforms as our ageing population becomes more disproportionate and chronic diseases become more prevalent.<sup>4</sup> In addition, the higher life expectancies and large numbers of baby boomers who are ageing is causing substantial pressure on the current health workforce which is not expanding at a proportionate rate.<sup>5</sup>

Eye health care workforce shortages are expected to increase in the future with over 480,000 older Australians in 2004 having vision impairment or blindness.<sup>6</sup> This is set to almost double by 2024 causing a considerable imbalance between the relative number of eye health care professionals in the workforce and the number of people requiring treatment.<sup>6</sup> This data includes individuals with chronic diseases such as glaucoma and diabetic retinopathy who require lifelong monitoring.

There is a need to review the scope of practice of orthoptists to assist in meeting the increasing demand for services. Nevertheless to date very little research has been conducted in areas designed to specifically look at orthoptists who are undertaking advanced scope of practice roles. Indeed in response to increasing demand, many hospitals, such as the Royal Victorian Eye and Ear Hospital, Northern Health, Alfred Health and Royal Children's Hospital in Victoria have up-skilled the orthoptic workforce to deliver various new services such as front-end triage clinics, diabetic screening, glaucoma monitoring and cataract assessment clinics. The orthoptists currently working in these programs do so

within a specialist setting and support of ophthalmologists and follow specially designed guidelines. The use of these guidelines can be seen in this issue's paper by Debra Gleeson who describes the interdisciplinary Glaucoma Monitoring Clinic (EGMON) at the Royal Victorian Eye and Ear Hospital and notes that the hospital has adopted the National Health and Medical Research Council (NHMRC) and American Academy of Ophthalmology guidelines to support current best practice.<sup>7</sup> Despite this, the peer-reviewed scientific evidence to support the effectiveness, efficiency and safety of extended scope of practice of orthoptists remains limited. This lack of scientific evidence could potentially be traced back to the size of the profession, which is relatively small, and the number of academics who are undertaking research specifically in a research field dedicated to orthoptics.

The broadening of the scope of practice of a health professional should only occur if specific needs for change can be identified.<sup>8</sup> Factors such as long waiting lists and patient needs which cannot be overcome with the current health workforce are for instance often the driving forces behind change. Introducing the role on the basis of simply allowing someone to further their career will most likely lead to an unsuccessful outcome.<sup>8</sup> Given that patients with chronic conditions such as glaucoma require lifelong treatment and that new referrals for eye care services are continually being received, a large number of patients are increasingly being reviewed within outpatient departments adding to the demand for qualified staff.<sup>9</sup> Between the years of 1998-99 and 2002-03 there was a 7% increase in Victorian Ambulatory Classification and Funding System (VACS) outpatient encounters for ophthalmology.<sup>10</sup> This saw ophthalmology become the third largest provider with 89,364 encounters in 2002-03.<sup>10</sup> When looking at ways to alleviate these pressures on the health service we need to look at workforce capacity. Census data from 2006 indicated that there were 769 ophthalmologists practising within Australia<sup>11</sup> and 678 orthoptists.<sup>12</sup> Making better use of the current eye health care workforce and increasing the scope of practice of orthoptists could potentially, in part, address the ever increasing public hospital outpatient waiting lists.

With the increased demand and a finite number of appointments available, patient care can be compromised as the waiting list is further extended. As this issue reaches a crisis point it results in an opportunity to reflect on service delivery models and to finding ways to provide a more efficient service which maintains quality and safety.<sup>9</sup> Despite the varied challenges in expanding the role of a practitioner, its introduction may have the potential to improve access to care, lead to greater efficiencies and can benefit rural and remote communities where a traditional health care provider is not available.<sup>13</sup> In addition, it is also often more cost-effective to utilise the skills of allied health professionals.<sup>13</sup> The task of our profession, at this cross-road, is to now build the evidence for innovation within eye health care that safely addresses the increased needs of

patients and to foster science-led practice to address future workforce challenges.

**Jane Scheetz, Konstandina Koklanis, Maureen Long, Meg E Morris**

Departments of Clinical Vision Science, Social Work and Physiotherapy, School of Allied Health, La Trobe University, Melbourne

## REFERENCES

1. Roper-Hall G. Historical vignette: Ernest Edmund Maddox (1860-1933): master surgeon, inventor, and investigator. *Am Orthopt J* 2009;59:103-110.
2. Doyle M. Associate professor in orthoptics. *Aust Orthopt J* 1991;27: iv.
3. Australian Institute of Health and Welfare. Vision problems among older Australians. Canberra, Australia, 2005 [cited 2013 5th Jun] Available from <http://www.aihw.gov.au/WorkArea/DownloadAsset.aspx?id=6442453390>.
4. Department of Health & Ageing. National Health Reform: Improving primary health care for all Australians. Canberra, Australia, 2011 [cited 2013 5th Jun] Available from [http://www.yourhealth.gov.au/internet/yourHealth/publishing.nsf/Content/improving-primary-health-care-for-all-australians-toc/\\$FILE/Improving%20Primary%20Health%20Care%20for%20all%20Australians.pdf](http://www.yourhealth.gov.au/internet/yourHealth/publishing.nsf/Content/improving-primary-health-care-for-all-australians-toc/$FILE/Improving%20Primary%20Health%20Care%20for%20all%20Australians.pdf).
5. Segal L, Bolton T. Issues facing the future health care workforce: the importance of demand modelling. *Aust New Zealand Health Policy* 2009;6(1):12-12. doi:10.1186/1743-8462-6-12.
6. Taylor HR, Keffe JE, Vu HT, et al. Vision loss in Australia. *Med J Aust* 2005;182(11):565-568.
7. Gleeson D. The Multidisciplinary Glaucoma Monitoring Clinic at The Royal Victorian Eye and Ear Hospital. *Aust Orthopt J* 2013;45.
8. Kidd MR, Watts IT, Mitchell CD, et al. Principles for supporting task substitution in Australian general practice. *Med J Aust* 2006;185(1):20-22.
9. Hitchings R. Shared care for glaucoma. *Br J Ophthalmol* 1995;79(7):626.
10. Department of Human Services. Victorian ophthalmology service planning framework: discussion paper. Melbourne, Australia; 2004 [cited 2013 15th Jun] Available from [http://www.health.vic.gov.au/ophthalmology/opthservice\\_planning\\_%20discpaper.pdf](http://www.health.vic.gov.au/ophthalmology/opthservice_planning_%20discpaper.pdf).
11. Australian Institute of Health and Welfare. Eye health labour force in Australia. Canberra, Australia; 2009 [cited 2013 8th Jun] Available from <http://www.aihw.gov.au/WorkArea/DownloadAsset.aspx?id=6442459946>.
12. Health Workforce Australia. Australia's health workforce series - health workforce by numbers. Adelaide; 2013 [cited 2013 15th Jun] Available from <https://www.hwa.gov.au/sites/uploads/Health-Workforce-by-Numbers-FINAL.pdf>.
13. Gilmore LG, Morris JH, Murphy K, et al. Skills escalator in allied health: a time for reflection and refocus. *J Healthcare Leadership* 2011;3:53-58.



# The Relationship between the Clinical Assessment, Temporal Artery Biopsy and the Positive Diagnosis of Giant Cell Arteritis

Natalie Duffy, BAppSc(Orth) MTeach

Gordon Eye Surgery, Gordon, Australia

## ABSTRACT

**Purpose:** The purpose of this study was to examine the relationship between the clinical assessment, histology report and the positive diagnosis of giant cell arteritis.

**Methods:** In 2011, a retrospective study (2005-2011) of 40 diagnosed temporal artery biopsy patients was conducted at an ophthalmic practice in Sydney, NSW. All patients had been consulted by the same neuro-ophthalmologist prior to the biopsy. Relevant data was extracted from patients' records and entered into a database for statistical analysis. A scoring system was developed for each sign and symptom to facilitate analysis. Patients with incomplete or inaccurate records were excluded from the study.

**Results:** A total of 40 patients were included in the study. The average age of participants was 78 years (range 55 to 92). At initial presentation, common signs included

headache (87%), jaw claudication (45%) and a change in vision (50%). Blood testing revealed raised inflammatory markers of erythrocyte sedimentation rate (ESR) (55%) and C-reactive protein (CRP) (90%) at presentation. A positive final diagnosis of temporal arteritis was made in 72.5% of all patients, despite only 52.5% of cases returning a positive temporal artery biopsy result.

**Conclusion:** This study has supported the importance of a temporal artery biopsy in combination with a detailed clinical assessment in the diagnosis of giant cell arteritis. In an ophthalmic setting a temporal artery biopsy is a useful tool to assist diagnosis, however with a false-negative risk careful clinical evaluation by the orthoptist and neuro-ophthalmologist will ensure that giant cell arteritis is promptly detected in patients.

**Keywords:** giant cell arteritis, histology, clinical assessment, positive diagnosis

## INTRODUCTION

Giant cell arteritis (GCA) is the most common form of systemic large-vessel vasculitis in adults over the age of 50 years.<sup>1</sup> The condition typically involves inflammation of large and medium-sized arteries, and classic manifestations include headache, jaw claudication, visual symptoms and polymyalgia rheumatica.<sup>2</sup> It is essential that clinicians are able to quickly and confidently establish the diagnosis of GCA to prevent irreversible visual loss, which occurs in 10 to 15% of patients.<sup>2,3</sup>

The prevalence of GCA in North America and Europe is approximately 200 cases per 100,000 population and the incidence is 20-30 per 100,000.<sup>4</sup> The average age of diagnosis is 70 years.<sup>5</sup> Women are more likely to suffer from GCA than men (ratio 2.6:1).<sup>4,6</sup> There is a strong correlation between temporal arteritis and polymyalgia rheumatica, with 50% of GCA patients suffering from both

conditions.<sup>7</sup> However, only 30% of polymyalgia rheumatica patients develop GCA. Giant cell arteritis is treated with corticosteroids, which alleviates symptoms usually within 24 to 72 hours and prevents irreversible visual loss.<sup>3</sup> The condition tends to be self-limiting over months to several years, but recurrences are seen in some patients.<sup>8</sup>

Temporal artery biopsy has been the traditionally-accepted method of diagnosing GCA.<sup>9</sup> It has been reported that histological tissue examination has a sensitivity of 24-90% and a specificity of 81-100%.<sup>8</sup> This large variation may be due to only a small segment of the artery removed for biopsy or the characteristic skip lesions of the condition resulting in an unaffected segment being examined. As such, it is accepted that a temporal artery biopsy is a useful tool in diagnosis but it should never be accepted as the solitary indicator of giant cell arteritis.<sup>9</sup> Patients with a typical clinical picture and positive response should be regarded as having GCA despite a negative biopsy result.<sup>10</sup>

The aim of the present investigation was to examine the relationship between the ophthalmologist's diagnosis of giant cell arteritis and the histology report. The overall

Correspondence: Natalie Duffy  
Email: n.duffy@live.com.au



objectives of the investigation were to (i) to examine the relationship between signs, symptoms, pathology and the positive diagnosis of giant cell arteritis, (ii) to compare the diagnosis of giant cell arteritis between the histology report and the ophthalmologist’s final diagnosis and (iii) to compare our findings against the literature.

**METHOD**

A retrospective study was conducted at an ophthalmic practice in Sydney, where clinical staff reviewed medical records to identify all temporal artery biopsy patients between 2005 and 2011. All patients were previously seen by the same neuro-ophthalmologist in the ophthalmic clinic or in a hospital consultation prior to the biopsy. The biopsy was performed as soon as the neuro-ophthalmologist considered a diagnosis of GCA. The procedure was performed at local hospitals under local anesthesia. The site of the biopsy was left to the discretion of the neuro-ophthalmologist and the size was approximately 2 cm in length.

Relevant data was extracted from the identified patient records and entered into a database for statistical analysis. A scoring system was developed for each sign and symptom to facilitate analysis. Patients with incomplete or inaccurate records were excluded from the study.

**RESULTS**

There were 30 females (75%) and 10 males (25%) in the study. The average age of patients was 78.04 years (SD 8.82), ranging from 55 to 92 (Figure 1). A positive final diagnosis of temporal arteritis was made in 72.5% of all patients; however, only 52.5% of cases returned a positive temporal artery biopsy result (Table 1).

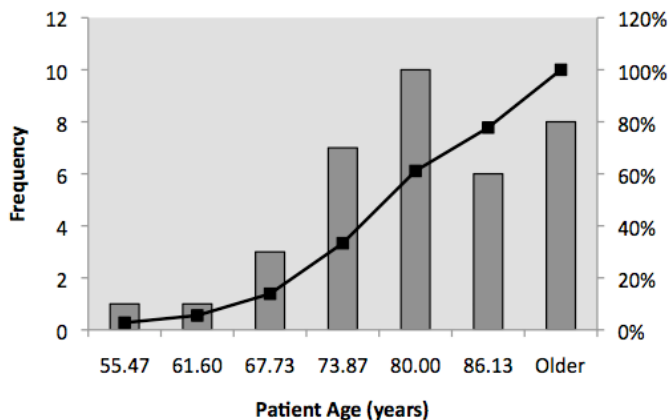


Figure 1. Distribution of patient age.

Age (years)	Number of patients	Number with positive GCA diagnosis (%)	
		Biopsy report diagnosis	Doctor’s final diagnosis
55-65	2	1 (50)	1 (50)
65-75	12	6 (50)	7 (58.3)
75-85	17	10 (55.5)	16 (88.8)
85-95	9	4 (44.4)	5 (55.5)
<b>Total</b>	<b>40</b>	<b>21 (52.5)</b>	<b>29 (72.5)</b>

A total of 15 markers were examined and interpreted by the orthoptist and neuro-ophthalmologist for detection of GCA (Table 2). Each marker was either scored 1 or 0 depending on whether the patient showed evidence of the marker or not. The maximum possible score was 15. For the total sample, there was a group average score of 6.56 (SD 1.7) indicating that on average patients had evidence of six to seven markers for GCA (Table 3). For the group of patients who had a negative biopsy but a positive final diagnosis the average marker score was slightly higher at 6.77 (SD 1.8) (Table 3). There was no apparent difference in evidence of markers between males and females.

Change in vision (blurring, loss of, diplopia)	Scalp tenderness
Headache	Loss of appetite
Jaw claudication	Unexplained weight loss
Neck stiffness	Elevated ESR
Night sweats	Elevated CRP
Joint pain	Tender temporal artery
Facial/ear pain	Enlarged temporal artery
	Non-pulsatile temporal artery

	Total group	Group with negative biopsy, final positive diagnosis
Average	6.56	6.77
Standard deviation	1.7	1.8

On initial presentation 87% of patients complained of a headache and 45% reported jaw claudication (Table 4). Visual symptoms such as unilateral or bilaterally blurred vision, episodes of loss of vision, visual distortions and diplopia were reported in 50% of all patients (Table 4). Four patients (10%) presented to the ophthalmic practice with a sudden and total loss of vision in one eye and a positive diagnosis of temporal arteritis was later confirmed from the biopsy (Table 4).

Table 4. Relationship between signs and symptoms and a positive GCA diagnosis

Clinical examination	Number of patients (%)	Number of patients (%)	
		Biopsy report diagnosis	Doctor's final diagnosis
Headache	33 (87)	20 (60)	26 (78.8)
Jaw claudication	18 (45)	12 (66.6)	17 (94.4)
Visual abnormality	20 (50)	10 (50)	15 (75)
Night sweats	7 (17.5)	5 (71.4)	7 (100)
Neck stiffness	10 (24.4)	5 (50)	9 (90)
Scalp tenderness	12 (30)	7 (58.3)	8 (66.7)
Loss of appetite	13(32.5)	5(38.4)	9 (69.2)
Tender temporal artery	19 (47)	9 (47.3)	14 (73.7)
Enlarged temporal artery	15 (37.5)	11 (73.3)	13 (86.7)
High ESR (>35)	22 (55)	10 (45.5)	15 (68.2)
High CRP (>5)	36 (90)	20 (55.6)	25 (69.4)
High ESR and CRP	22 (55)	10 (45.5)	16 (72.7)

Clinical examination conducted by the neuro-ophthalmologist revealed a tender temporal artery in 47% of patients, and it was enlarged and non-pulsatile in approximately 37-40% of all patients. Normal intraocular pressures (range 10-21 mmHg) were noted in 36 patients for the right eye (mean=15, SD 4.6) and 38 patients for the left eye (mean=14, SD 4.1).

Blood testing of inflammatory markers prior to the biopsy revealed that 55% of patients had an erythrocyte sedimentation rate (ESR) level above normal for their age bracket and gender. A positive final diagnosis was made in 68.2% of all patients who presented with a pre-biopsy abnormal ESR level. However, only 45.5% of these patients returned a positive biopsy result. An above normal C-reactive protein (CRP) level was evident in 90% of cases pre-biopsy. Of these, 69.4% of patients with a high CRP had a positive final GCA diagnosis. However, only 55.6% of these patients recorded a positive biopsy result.

Thirty-four of the 40 patients (85%) commenced corticosteroid treatment prior to the biopsy procedure. Due to their signs, symptoms and high inflammatory parameters, three patients were administered intravenous corticosteroid therapy, methyl prednisolone, a more aggressive high-dose intervention than oral intake.

## DISCUSSION

It is well known that the single greatest risk factor for developing giant cell arteritis is ageing.<sup>2</sup> A published review of 1,435 of positive-biopsy cases revealed that only two patients were under the age of 50.<sup>11</sup> This suggests that clinicians should primarily consider GCA as a condition of

the elderly with only strong clinical evidence warranting suspicion in younger people.<sup>2,3,11</sup> These findings agree with our results, where the number of patients with a final positive diagnosis steadily increased with age (Table 1). In addition, women are more likely to suffer from the condition than men and this is represented in our study with a dominant female population (30 females vs 10 males).

The results of the study have supported the literature and shown that a biopsy alone does not provide sufficient information to determine a diagnosis of giant cell arteritis. The biopsy underestimated the total number of patients with a positive final diagnosis by approximately 20% (Table 1). This underestimation could be attributed to factors including the nature of the disease, where it is characterised by skip lesions or the small size of the biopsied area.<sup>2,5,9</sup>

Headache (87%) and jaw claudication (45%) were two common symptoms reported by patients at initial presentation to the orthoptist (Table 4). It has been reported that a headache is an important sign of GCA but it is not always reliable in the diagnosis of the condition because it can be due to many other diseases.<sup>6</sup> This is supported in our study with 26 of the 33 (78.8%) patients with a reported headache ending with a final positive diagnosis of GCA (Table 4). In comparison jaw claudication is less commonly reported yet it is a relatively specific indicator for GCA, as indicated in our study through 94.4% of patients with this symptom having a final positive diagnosis of the condition (Table 4).<sup>11</sup>

Analysis of the blood inflammatory markers showed that 55% of patients had an ESR level above normal and 90% had an abnormally elevated CRP level prior to the temporal artery biopsy (Table 4). In the literature there is great variation in what is considered to be a normal ESR rate.<sup>6</sup> As such patients may still have GCA even in the presence of a normal/low ESR level so whilst it is a useful inflammatory marker, it should be treated with caution.<sup>6</sup>

The CRP level is thought to be a more useful marker in diagnosing and monitoring GCA, as it is highly sensitive to inflammation and unlike ESR it is not influenced by age or gender.<sup>6</sup> Interestingly in this study, only 69.4% of patients with a high CRP had a final positive diagnosis of GCA (Table 4). This lower sensitivity might be explained by differences in normal CRP levels for different laboratories, which were not recorded in the research database. As a result of this lack of information and to enable some analysis it was decided by the neuro-ophthalmologist to consider a CRP level above 5 as abnormal.

If GCA was suspected at initial presentation the neuro-ophthalmologist immediately commenced patients on a high dose of corticosteroids in an effort to prevent irreversible visual loss. It could be argued that corticosteroid therapy

prior to the biopsy masked the condition and resulted in a false-negative report. However, this is heavily refuted in the literature where it has been reported that the characteristics and inflammatory markers of GCA can be seen in the artery for two to six weeks after initiation of treatment.<sup>1,3,6</sup>

It is likely that the ophthalmologist overruled the negative biopsy result in patients who had a strong presentation of clinical signs and symptoms, pathology and a positive response to corticosteroid intervention (Table 4). This is evident in the marker scores as they show that the overall group vs the overruled negative biopsy group had a similar score for GCA, that is, prior to the biopsy they were equally suspected of having GCA (Table 3). The incidence of false-negative biopsy results in our study agrees with the literature, where it has been reported that a temporal artery biopsy has poor sensitivity. From this we can conclude that it is essential to complete a thorough clinical examination as the detection of GCA can be dependent on this.

Thus, it can be accepted that a temporal artery biopsy is a useful tool in the diagnosis of GCA but it should not be used as the solitary indicator. A positive biopsy result is a clear indicator for GCA but it can produce false-negative results.<sup>1</sup> Careful clinical evaluation must be performed for all patients who are suspected of having GCA. These findings are well-supported in our study; 94% of patients who reported jaw claudication and 86.7% patients with an enlarged temporal artery were later found to have a final positive diagnosis of GCA (Table 4). Other reported symptoms such as a headache, night sweats and neck stiffness were also strongly associated with a final positive diagnosis.

## CONCLUSION

Temporal artery biopsy is an important tool to be used in the diagnosis of giant cell arteritis. However, with the risk of a false-negative result (20% of our cases) it is not the solitary indicator for GCA. Orthoptists are crucial members of the clinical assessment team and they have an important role in the detection of GCA. This study reinforces that it is essential for both the orthoptist and ophthalmologist to take a detailed history and conduct a thorough examination including blood testing to reveal indicators for GCA. A failure to do so may result in undetected GCA, leading to an irreversible loss of vision in patients.

## ACKNOWLEDGEMENTS

Dr Sara Booth-Mason and the ophthalmic team at Gordon Eye Surgery, Gordon, NSW.

Linda Santamaria, Editor, Australian Orthoptic Journal.

## REFERENCES

1. Barraclough K, Mallen CD, Halliwell T, et al. Diagnosis and management of giant cell arteritis. *Br J Gen Pract* 2012;62(599):329-330.
2. Levine SM, Hellmann DB. Giant cell arteritis. *Curr Opin Rheumatol* 2002;14(1):3-10.
3. Gonzalez-Gay MA, Rodriguez-Valverde V. Vasculitis Syndromes: not losing sight is the issue in GCA management. *Nat Rev Rheumatol* 2010;6(8):440-441.
4. Richards BL, March L, Gabriel SE. Epidemiology of large-vessel vasculidities. *Best Pract Res Clin Rheumatol* 2010;24(6):871-883.
5. Mashaleh M, Spencer D, Howe G, Manolios N. Temporal artery biopsies - a retrospective review over a two-year period in an Australian major teaching hospital. *J Royal Med Services* 2010;17(4):61-63.
6. Hayreh SS, Zimmerman B. Management of giant cell arteritis: our 27-year clinical study: new light on old controversies. *Ophthalmologica* 2003;217(4):239-259.
7. Salvarani C, Cantini F, Boiardi L, Hunder GG. Polymyalgia rheumatica and giant-cell arteritis. *N Engl J Med* 2002;347(4):261-271.
8. Ray-Chaudhuri N, Kine DA, Tijani SO, et al. Effect of prior steroid treatment on temporal artery biopsy findings in giant cell arteritis. *Br J Ophthalmol* 2002;86(5):530-532.
9. Alberts MS, Mosen DM. Diagnosing temporal arteritis: duplex vs. biopsy. *QJM* 2007;100(12):785-789.
10. Dasgupta B, Borg FA, Hassan N, et al. BSR and BHRP guidelines for the management of giant cell arteritis. *Rheumatology (Oxford)* 2010;49(8):1594-1597.
11. Smetana GW, Shmerling RH. Does this patient have temporal arteritis? *JAMA* 2002;287(1):92-101.



# A Case Study and Literature Review of Coexisting Dissociated Vertical and Horizontal Deviations

Cassandra Norris, BSc BA MOrth<sup>1</sup>  
Linda Santamaria, MAppSc DipAppSc(Orth)<sup>2</sup>

<sup>1</sup>Department of Clinical Vision Sciences, La Trobe University, Melbourne, Australia

<sup>2</sup>Department of Surgery, Monash University, Melbourne, Australia

## ABSTRACT

Adequate treatment of dissociated deviations has eluded eye care professionals since its discovery in 1895. This case-based investigation presents a review of the various treatment methods that have been advocated for both dissociated vertical and dissociated horizontal deviations,

particularly in the presence of a consecutive exotropia and inferior oblique overaction. This difficult case provided an excellent opportunity to elucidate how surgery options change in the presence of multiple ocular anomalies.

**Keywords:** infantile esotropia, consecutive exotropia, dissociated vertical deviation, dissociated horizontal deviation

## INTRODUCTION

**E**ssential infantile esotropia, previously termed congenital esotropia, is defined as a manifest eso-deviation with an onset between birth and six months.<sup>1</sup> It is the most common form of strabismus, with a reported incidence of 0.1% to 1.0%.<sup>2</sup> Early treatment is aimed at surgically straightening the eyes in order to improve cosmesis and promote the development of binocular vision, though the outcome of orthotropia with full stereoacuity is considered rare.<sup>1-3</sup> Prior to surgical intervention, non-surgical treatment includes correction of any refractive error and occlusion for amblyopia until equal visual acuity or alternation of fixation is achieved.<sup>1</sup> After surgery, children require continued review for observation of amblyopia and visual development and also stability of the deviation, as further operations may be required for residual esotropia, consecutive exotropia or vertical muscle imbalance.

Infantile esotropia includes a constellation of associated features including primary inferior oblique overaction with or without an associated V-pattern, dissociated vertical deviation and latent nystagmus<sup>1,4-6</sup> which are rarely evident at the time of diagnosis but generally occur after two years of age.<sup>1,4</sup> Primary inferior oblique overaction is defined as increased elevation in the adducted eye on version testing without an associated superior oblique palsy.<sup>7,8</sup> These overactions have been reported in 63% to 78% of children with infantile esotropia,<sup>4,8</sup> the incidence depending upon the age of the children, most frequently presenting in the

second year of life and generally apparent by 7 years of age.<sup>4</sup>

Dissociated vertical deviation (DVD) is characterised by a slow elevation, abduction and extorsion of the non-fixing eye under cover, or when the patient is inattentive or fatigued.<sup>9</sup> DVD has been reported in 49% to 76% of children with infantile esotropia,<sup>3,4,8-11</sup> with the mean onset reported as 2.8 years with none developing after 6 years of age.<sup>9</sup> Infantile esotropia with both inferior oblique overaction and DVD has been reported in 45% to 59%.<sup>4,8</sup>

Another less frequently reported variant of a dissociated strabismus complex<sup>12,13</sup> is dissociated horizontal deviation (DHD), defined as a change in horizontal alignment associated solely with a change in the balance of input from the two eyes, usually manifesting as a spontaneous exo-deviation of greater magnitude in one eye during alternate prism cover test.<sup>13-15</sup> Generally the movement is slow, variable and asymmetrical in the two eyes.<sup>13-15</sup> Keskinbora and Puler,<sup>5</sup> in a long-term follow-up study of children with infantile esotropia noted DHD in 3% to 6%, however it was reported in 50% of 28 children with consecutive exotropia when performing the reversed fixation test specifically looking for DHD.<sup>15</sup>

## CASE REPORT

A five-year-old girl presented to the clinic, having been managed elsewhere as an infant. She was initially diagnosed at 8 months of age with a congenital esotropia (ET) and was prescribed a high hypermetropic correction at this time, although with poor results. Bimedial rectus recession surgery was undertaken at 12 months of age and no further problems were noted until 4 to 5 years of age. She then

Correspondence: **Cassandra Norris**  
Department of Clinical Vision Sciences,  
La Trobe University, VIC 3086, Australia  
Email: cassandra.norris12@gmail.com

presented to this clinic when her mother noticed her left eye turning out intermittently, approximately 50% of the time. She had continued wearing the glasses prescribed by her previous ophthalmologist (RE +7.25DS and LE +8.25DS) and her current visual acuity was RE 3/4 and LE 3/6 with single optotypes. On examination, with glasses she had a consecutive left exotropia (XT) of 4-6 prism dioptres (PD) at near increasing to 45-50 PD at distance. Without correction a moderate alternating ET of 20 PD was evident. Asymmetric DVD was present bilaterally, greater in the right eye. On ocular movements, bilateral inferior oblique overaction and a significant Y-pattern were noted. Without glasses a chin-down head posture was apparent, which in the presence of the Y-pattern resulted in a reduction of the esotropia. She demonstrated no stereopsis or evidence of binocular single vision.

Cycloplegic refraction demonstrated that her current glasses did not include her astigmatic correction and overcorrected her left hypermetropia. It was decided to prescribe a one-dioptre undercorrection of RE +7.00/-1.50 x 180 and LE +7.00/-2.50 x 180 in order to encourage accommodative convergence to reduce the size of the exotropia. Two months later with the new glasses, visual acuity was 6/9 each eye with Snellen chart. With glasses a 25 PD left to alternating exotropia was present at distance, with 12 PD LXT measured at near. Also noted was the presence of a dissociated strabismus complex, with both horizontal and vertical components. For distance fixation, she tended to alternate fixation and when fixing with the right eye the left exotropia was greater, however when fixing with the left eye the exotropia was less but the right hypertropia was more apparent. At this visit a 10 PD V-pattern was noted on ocular movements as opposed to the Y-pattern described at the previous visit.

She was scheduled for bilateral inferior oblique anterior transposition surgery, aiming to reduce both the DVD and inferior oblique overaction. Although it was not clinically significant, this operation may have been expected to reduce the V-pattern and could also decrease the exotropia. Postoperatively, a 2 PD LXT was present at near with glasses, increasing to 8 PD at distance, with both the V-pattern and inferior oblique overaction reduced.

## DISCUSSION

Initially the patient was thought to have an infantile esotropia, however this diagnosis in the presence of high hypermetropia lead to questioning the possibility of an alternate diagnosis such as an early-onset accommodative esotropia.

As she presented at 8 months of age, it would generally be considered that her esotropia was of the infantile esotropia variety. The more common presentation for accommodative

esotropia is generally between the ages of one and three years,<sup>16</sup> though there are instances where it has been reported earlier than 6 months of age. One study of a group of children with esotropia with an onset before 6 months found 14% had hypermetropia of greater than 2.5 dioptres, and that almost half of these had an accommodative esotropia in which control was achieved with refractive correction alone, while the remainder required surgical correction and as such, would be diagnosed with an infantile esotropia.<sup>6</sup> Another study reported 3.6% of their group of children with unilateral infantile esotropia were controlled with hypermetropic correction.<sup>17</sup>

The majority of children with an infantile esotropia have an insignificant refractive error, however a small number of children have high hypermetropia. Several studies have reported the incidence of hypermetropia in children with infantile esotropia; 11% to 17% greater than 2.5 or 3.0 dioptres,<sup>4,6,17,18</sup> 18% greater than 4.0 dioptres,<sup>5</sup> and 9% greater than 6.0 dioptres.<sup>19</sup> In the presence of her high hypermetropia and the early onset, she would be considered to have a partially accommodative esotropia; an infantile esotropia with an accommodative element superimposed, where the deviation is decreased by 10 prism dioptres or more when the accommodative component is corrected.<sup>1,16</sup> As her esotropia did not improve significantly with hypermetropic correction, bimedial rectus recession surgery was performed at 12 months of age.

After many years of retrospective studies, case series and prospective studies considering the surgical treatment for infantile esotropia and the choice of bimedial rectus recession or unilateral recession/resection, a randomised, controlled, multicentre trial has found no significant difference in the postoperative angle using either surgical approach.<sup>20</sup> In this study all of the children were operated on between the ages of 3 and 8 years, which would be considered late surgery.

Similar to the discussion regarding type of surgery, there has been long-standing debate regarding the optimum timing of surgical intervention to allow for the potential development of binocularity. The Early vs Late Infantile Strabismus Surgery Study (ELISS), a large controlled, prospective multicentre study comparing early (6 to 24 months) and late surgery (32 to 60 months), reported that gross stereopsis with the Titmus Fly was achieved by 13.5% of the early group and 3.9% of the late group, however finer levels of stereopsis were achieved by only 3.0% and 3.9% respectively.<sup>11</sup> Earlier studies have suggested 12 months as the optimal time, reporting gross random dot stereopsis in 35% to 41% of those operated before 12 months, however the number achieving finer levels of stereopsis was small.<sup>10,17</sup> One report of 'very early' surgery examined a small group of children operated prior to 6 months and found gross stereopsis in 75%, but none with finer levels.<sup>3</sup> In summary, the authors generally supported surgery prior to 24 months<sup>2,11</sup> or 12 months of age<sup>3,10,17</sup> as with our case,

however despite this optimal timing she did not achieve binocularity. There appears no strong justification for surgery before 6 months, noting the difficulty of diagnosis, assessment and intervention in this short timeframe and the finding that those who have early surgery are more likely to require subsequent operations.<sup>3,10,11,17</sup>

Consecutive exotropia such as that exhibited by the subject, is a manifest exo-deviation that develops in a previously esotropic patient<sup>19</sup> and is reported in 12% to 26% of children who have undergone surgery for esotropia.<sup>4,5,10,19,20</sup> This may not develop until some years after surgery, with many occurring more than 5 years later, often after years of 'successful' alignment,<sup>4,18</sup> as was the case with our child. The presence of limited adduction and multiple operations is associated with an increased risk of consecutive exotropia,<sup>18,19</sup> however neither of these factors were present in this case. Reduction of the hypermetropic correction to induce accommodative convergence is recommended as nonsurgical management.<sup>1,16</sup> In our patient's case this had some effect, but further treatment was still required.

In 1895, Stevens first described dissociated vertical deviation, explaining the presence of an 'alternating vertical strabismus'.<sup>12,21</sup> The pathophysiology of dissociated strabismus complexes are still under investigation, however they are known to have strong associations with nystagmus and the presence of strabismus early in life.<sup>12,22</sup> DVD is generally asymptomatic, usually bilateral and frequently asymmetrical,<sup>23</sup> and as shown by our subject, frequently becomes apparent after strabismus surgery. Interestingly, the timing of initial strabismus surgery appears to have no impact on the likelihood of developing DVD.<sup>9</sup> Simonsz et al suggested that decompensated DVD occurred more frequently with consecutive exotropia (72%) than with residual esotropia (50%),<sup>11</sup> such as was demonstrated by this patient, where the dissociated deviations coexisted with a consecutive exotropia.

DVD does not respond to orthoptic management,<sup>23</sup> so surgery is the only viable option available to alleviate this problem,<sup>22</sup> but is considered only when the deviation becomes cosmetically unacceptable.<sup>1,23-25</sup> Various procedures aim to weaken the elevator muscles or strengthen the depressor muscles as a means of correcting DVD, albeit with varying degrees of success.<sup>22,25</sup> One earlier study reported the success of large inferior rectus resections for children with DVD, stating that they were as valuable as superior rectus recessions and easier to perform.<sup>21</sup> However, the complications of restriction of elevation and palpebral fissure changes were generally considered to be unacceptable,<sup>23,25,26</sup> though correction may be considered as a secondary procedure.<sup>23,26</sup>

Conventional superior rectus recessions (3-5 mm) were found to be ineffective in treating DVD.<sup>26</sup> 1976 saw the introduction of an operation described by Cüppers which involved the weakening of an extraocular muscle by

suturing the muscle to the sclera posterior to its insertion, originally termed a fadenoperation, now commonly known as a Faden operation.<sup>23</sup> Sprague et al reported the outcomes of a 14 mm superior rectus Faden procedure combined with a graded 3-5 mm recession on 34 patients, 23 of whom gained good postoperative results. One later paper compared the outcomes of a 12-14 mm Faden procedure with or without a 3 mm superior rectus recession and reported that the combined procedure gave the best long-term effect, avoiding undercorrection particularly in cases of DVD greater than 14 prism dioptres.<sup>25</sup> In comparing a Faden/recession combination with a large superior rectus recession (7-9 mm), Esswein et al reported that though the results were similar in the short-term with 86% corrected or improved, the large recession produced the best long-term result, with 72% maintaining the result.<sup>26</sup> In contrast, Lorenz et al found the Faden/recession combination gave better long-term results compared to a 10 mm recession.<sup>25</sup> In cases where the DVD is asymmetric, bilateral surgery with a graded recession was recommended.<sup>23,25,26</sup> It must be noted that all of these reports were retrospective case series, reporting on the surgery of choice at any period in time.

A further method of reducing the overall elevation effect is an inferior oblique anterior transposition, which was performed on our patient to treat both her DVD and inferior oblique overaction. This procedure is based on the hypothesis that transposing the inferior oblique anteriorly to the temporal corner of the inferior rectus muscle insertion site increases the recession effect, converting the muscle into a depressor.<sup>27,28</sup> Kratz et al determined anteriorisation of the inferior oblique to be effective in the treatment of DVD, and that grading the anteriorisation improved the surgical outcomes,<sup>27</sup> a finding later contradicted by Engman et al who determined that grading is no more effective than the standard surgical procedure.<sup>29</sup> This procedure has been favoured for the treatment of DVD associated with inferior oblique overaction, such as in this case,<sup>28</sup> though it has also been reported that DVD improvement showed no significant difference between those with or without inferior oblique overactions.<sup>22</sup> One case series reported the use of bilateral inferior oblique anterior transposition as a treatment for bilateral inferior oblique overaction, and found a subsequent prevention or reduction in DVD, with only one case in 61 children requiring subsequent DVD surgery compared to nine in a control group of 60 children.<sup>30</sup> It was found to be more effective for smaller degrees of DVD, but less predictable and less stable long-term if the vertical deviation exceeds 15 prism dioptres.<sup>22,29,31</sup> A combination of inferior oblique anterior transposition and resection has been suggested for moderate to large DVD.<sup>24</sup>

It has been found that inferior oblique anteriorisation may result in adverse side effects, such as narrowing of the palpebral fissure and a bulging of the lower lid on elevation.<sup>28</sup> A mild limitation of elevation was noted in 20% to 27% of



cases, but was not of clinical or cosmetic concern.<sup>24,31</sup> The debate continues as to whether bilateral surgery should be performed in the presence of unilaterally manifesting DVD,<sup>32</sup> but it has been suggested that the limitation of elevation is less apparent with bilateral surgery.<sup>13-15,22</sup>

In 1976 Raab observed what is now known as dissociated horizontal deviation, terming it a horizontal variant of dissociated vertical divergence.<sup>14,15</sup> DHD is described as the occurrence of a slow and variable horizontal deviation, which changes in magnitude depending on which eye is fixing.<sup>14</sup> This ocular alignment anomaly is unrelated to accommodation, and needs to be distinguished from an unequal amount of accommodation exerted by the eyes by ensuring assessment with the full refractive correction.<sup>14,33</sup> Post-surgical changes to the extraocular muscles such as over-recession of the medial rectus, over-resection of the lateral rectus, fibrosis of the lateral rectus or a slipped medial rectus would result in differing primary and secondary deviations,<sup>14,33,34</sup> however the deviation would not be a slow movement as is seen in dissociated complexes. Ocular movements would also demonstrate gaze incomitance with these muscle weaknesses or restrictions.<sup>14,33,34</sup>

It is suggested that diagnosis of DHD include prism cover test in all positions of gaze, testing with both eyes fixing alternately to show that the size of exodeviation differs only depending on which eye is fixing,<sup>14,33</sup> though some note the difficulty in quantifying the angle in the same way as DVD<sup>33,34</sup> and suggest that an estimation of the angle may be required.<sup>34</sup> In the Bielschowsky Darkening Wedge Test patients will show a result similar to that observed in DVD, but in the horizontal plane.<sup>13,14</sup> There may also be an associated torsional component, DVD and/or latent or manifest latent nystagmus.<sup>14,15,34</sup> A positive reversed fixation test result is also indicative of the presence of DHD.<sup>14,15,33</sup> The slow movement will be observable on cover testing, so occluding the eye for a longer period allows time for the dissociated deviation to appear.<sup>33,34</sup> Also evident is an increase in the size of the deviation during periods of visual inattention,<sup>14,15,33,34</sup> and this is further shown when the deviation is a greater magnitude under anaesthesia than during prism cover testing.<sup>14,15,33</sup>

A study by Brodsky and Fray found 50% of 28 patients with consecutive exotropia following infantile esotropia surgery demonstrated DHD, and reported a correlation with the findings of DVD, but not with latent nystagmus, however eye movement recordings were not undertaken to determine the presence of subclinical latent nystagmus.<sup>15</sup> Brodsky then concluded that monocular fixation with either eye generates a dissociated esotonus in patients with DHD, superimposed upon a baseline exo-deviation in those with a consecutive exotropia.<sup>15</sup> He hypothesised that DVD, DHD and latent nystagmus present a trilogy of dissociated ocular motor responses to unequal visual input, and refuted the earlier theory presented by Zubcov et al that DHD could

be the manifestation of an asymmetric nystagmus blockage syndrome.<sup>35</sup>

Similar to DVD, treatment of DHD is only considered when the deviation is manifesting and cosmetically unacceptable, and the only non-surgical management available is to attempt to promote fixation with the eye that deviates most often so as to improve the cosmetic effect.<sup>34</sup> Wilson et al, after a long-term follow-up study of 32 patients who had surgery for DHD, recommended unilateral lateral rectus recession of 5-8 mm for those with DHD alone, and bilateral recessions of 5-8 mm in the presence of an exotropia, with 78% requiring only one operation and a residual latent DHD remaining in 31% long-term.<sup>34</sup> In contrast, Brodsky<sup>14</sup> reported that a medial rectus advancement procedure is a more effective treatment for consecutive exotropia than a lateral rectus recession, arguing that the horizontal alignment may apparently be improved, however the exotropia still exists under conditions of visual inattention. In the presence of DHD and consecutive exotropia he recommended bilateral medial rectus advancements when there is lateral incomitance or a greater deviation at near, or large bilateral rectus recessions if the distance deviation is greater, though no results are described.

As the majority of those with DHD also have DVD, simultaneous horizontal and vertical surgery may be required. In an analysis of a retrospective series of 20 patients with both DVD and DHD, 15 had surgery for DHD, with 10 of these having unilateral horizontal surgery combined with bilateral vertical surgery.<sup>33</sup> Wilson and McClatchey noted that DHD can be corrected with more conservative amounts than the large recessions recommended for DVD, again recommending simultaneous lateral and superior rectus recessions.<sup>13</sup>

## CONCLUSION

This case illustrates the complexity of managing coexisting dissociated horizontal and vertical deviations. Although it is recommended that a prism cover test is done in all positions of gaze with each eye fixing, the child was diagnosed with dissociated horizontal deviation following observation of a difference in the size of deviation depending on which eye was fixing. The difficulty lies in the decision as to whether to operate on the horizontal or vertical deviation, or to do a combined procedure in the presence of combined dissociated deviations. In this child's case, surgery on the inferior obliques to improve the inferior oblique overaction as well as the dissociated vertical deviation was undertaken; however, this surgery also decreased the appearance of the horizontal deviation and the V-pattern. This case study showed a successfully treated individual with a complex case of coexisting dissociated horizontal and vertical deviations, inferior oblique overaction and V-pattern.

## REFERENCES

1. von Noorden G, Campos E. *Binocular Vision and Ocular Motility: Theory and Management of Strabismus*. 6th Ed. St Louis: Mosby; 2002.
2. Elliott S, Shafiq A. Interventions for infantile esotropia. *Cochrane database of systematic reviews (Online)* 2005(1):CD004917.
3. Ing MR. Surgical alignment prior to six months of age for congenital esotropia. *Trans Am Ophthalmol Soc* 1995;93:135-141; discussion 141-136.
4. Hiles DA, Watson BA, Biglan AW. Characteristics of infantile esotropia following early bimedial rectus recession. *Arch Ophthalmol* 1980;98(4):697-703.
5. Keskinbora KH, Pular NK. Long-term results of bilateral medial rectus recession for congenital esotropia. *J Pediatr Ophthalmol Strabismus* 2004;41(6):351-355.
6. Koc F, Ozal H, Firat E. Is it possible to differentiate early-onset accommodative esotropia from early-onset essential esotropia? *Eye (Lond)* 2003;17(6):707-710.
7. Ghazawy S, Reddy AR, Kipioti A, et al. Myectomy versus anterior transposition for inferior oblique overaction. *J AAPOS* 2007;11(6):601-605.
8. Wilson ME, Parks MM. Primary inferior oblique overaction in congenital esotropia, accommodative esotropia, and intermittent exotropia. *Ophthalmology* 1989;96(7):950-955; discussion 956-957.
9. Neely DE, Helveston EM, Thuente DD, Plager DA. Relationship of dissociated vertical deviation and the timing of initial surgery for congenital esotropia. *Ophthalmology* 2001;108(3):487-490.
10. Birch EE, Stager DR, Everett ME. Random dot stereoacuity following surgical correction of infantile esotropia. *J Pediatr Ophthalmol Strabismus* 1995;32(4):231-235.
11. Simonsz HJ, Kolling GH, Unnebrink K. Final report of the early vs. late infantile strabismus surgery study (ELISSS), a controlled, prospective, multicenter study. *Strabismus* 2005;13(4):169-199.
12. Guyton DL. Dissociated vertical deviation: etiology, mechanism, and associated phenomena. *Costenbader Lecture. J AAPOS* 2000;4(3):131-144.
13. Wilson ME, McClatchey SK. Dissociated horizontal deviation. *J Pediatr Ophthalmol Strabismus* 1991;28(2):90-95.
14. Brodsky MC. Dissociated horizontal deviation: clinical spectrum, pathogenesis, evolutionary underpinnings, diagnosis, treatment, and potential role in the development of infantile esotropia (an American Ophthalmological Society thesis). *Trans Am Ophthalmol Soc* 2007;105:272-293.
15. Brodsky MC, Fray KJ. Dissociated horizontal deviation after surgery for infantile esotropia: clinical characteristics and proposed pathophysiologic mechanisms. *Arch Ophthalmol* 2007;125(12):1683-1692.
16. Ansons A, Davis H. *Diagnosis and Management of Ocular Motility Disorders*. Oxford: Blackwell Publishing; 2001.
17. Birch EE, Stager DR, Berry P, Everett ME. Prospective assessment of acuity and stereopsis in amblyopic infantile esotropes following early surgery. *Invest Ophthalmol Vis Sci* 1990;31(4):758-765.
18. Folk ER, Miller MT, Chapman L. Consecutive exotropia following surgery. *Br J Ophthalmol* 1983;67(8):546-548.
19. Ganesh A, Pirouznia S, Ganguly SS, et al. Consecutive exotropia after surgical treatment of childhood esotropia: a 40-year follow-up study. *Acta Ophthalmol* 2011;89(7):691-695.
20. Polling JR, Eijkemans MJ, Esser J, et al. A randomised comparison of bilateral recession versus unilateral recession-resection as surgery for infantile esotropia. *Br J Ophthalmol* 2009;93(7):954-957.
21. Noel LP, Parks MM. Dissociated vertical deviation: associated findings and results of surgical treatment. *Can J Ophthalmol* 1982;17(1):10-12.
22. Nabie R, Anvari F, Azadeh M, et al. Evaluation of the effectiveness of anterior transposition of the inferior oblique muscle in dissociated vertical deviation with or without inferior oblique overaction. *J Pediatr Ophthalmol Strabismus* 2007;44(3):158-162.
23. Sprague JB, Moore S, Eggers H, Knapp P. Dissociated vertical deviation. Treatment with the faden operation of Cuppers. *Arch Ophthalmol* 1980;98(3):465-468.
24. Farvardin M, Attarzadeh A. Combined resection and anterior transposition of the inferior oblique muscle for the treatment of moderate to large dissociated vertical deviation associated with inferior oblique muscle overaction. *J Pediatr Ophthalmol Strabismus* 2002;39(5):268-272; quiz 293-264.
25. Lorenz B, Raab I, Boergen KP. Dissociated vertical deviation: what is the most effective surgical approach? *J Pediatr Ophthalmol Strabismus* 1992;29(1):21-29.
26. Esswein MB, von Noorden GK, Coburn A. Comparison of surgical methods in the treatment of dissociated vertical deviation. *Am J Ophthalmol* 1992;113(3):287-290.
27. Kratz RE, Rogers GL, Bremer DL, Leguire LE. Anterior tendon displacement of the inferior oblique for DVD. *J Pediatr Ophthalmol Strabismus* 1989;26(5):212-217.
28. Kushner BJ. The effect of anterior transposition of the inferior oblique muscle on the palpebral fissure. *Arch Ophthalmol* 2000;118(11):1542-1546.
29. Engman JH, Egbert JE, Summers CG, Young TL. Efficacy of inferior oblique anterior transposition placement grading for dissociated vertical deviation. *Ophthalmology* 2001;108(11):2045-2050.
30. Mims JL, 3rd, Wood RC. Bilateral anterior transposition of the inferior obliques. *Arch Ophthalmol* 1989;107(1):41-44.
31. Burke JP, Scott WE, Kutshke PJ. Anterior transposition of the inferior oblique muscle for dissociated vertical deviation. *Ophthalmology* 1993;100(2):245-250.
32. Wong CY, Ng JS, Goh TY. Combined resection and anterior transposition of the inferior oblique muscle for the treatment of moderate to large dissociated vertical deviation associated with inferior oblique muscle overaction. *J Pediatr Ophthalmol Strabismus* 2003;40(4):194-195.
33. Gamio S. Diagnosis and surgical treatment of dissociated horizontal deviation strabismus. *Binocul Vis Strabolog Q Simms Romano* 2011;26(1):43-50.
34. Wilson ME, Hutchinson AK, Saunders RA. Outcomes from surgical treatment for dissociated horizontal deviation. *J AAPOS* 2000;4(2):94-101.
35. Zubcov AA, Reinecke RD, Calhoun JH. Asymmetric horizontal tropias, DVD, and manifest latent nystagmus: an explanation of dissociated horizontal deviation. *J Pediatr Ophthalmol Strabismus* 1990;27(2):59-64; discussion 65.

# The Multidisciplinary Glaucoma Monitoring Clinic at The Royal Victorian Eye and Ear Hospital

Debra Gleeson, AssocDipAppSc(Orth)

Department of Diagnostic Eye Services (Orthoptics), The Royal Victorian Eye and Ear Hospital, Melbourne, Australia

## ABSTRACT

An ageing population worldwide is and will increasingly overburden existing eye health services due to an associated increase in age-related ocular disease. This has necessitated the development of different eye care schemes to alleviate this problem, particularly in the area of glaucoma. These schemes utilise community optometrists, and hospital-based optometrists, orthoptists and ophthalmic nurses. The various schemes have aided in a range of ways, from reducing false-positive glaucoma referrals to hospital clinics, to diagnosing, monitoring and in some cases treating suitable glaucoma patients.

The Royal Victorian Eye and Ear Hospital (RVEEH) Glaucoma Monitoring Clinic (EGMON) which started in 2007 utilises a multidisciplinary team of ophthalmic consultants, optometrists, orthoptists and ophthalmic nurses. The

EGMON Clinic was set up in response to increasing numbers attending the RVEEH glaucoma clinics, the largest tertiary glaucoma service in Victoria. This was affecting the availability of appointments for new and review patients.

Orthoptists have the theoretical knowledge and the clinical background to play an important role in the provision of services to patients with glaucoma and other types of chronic eye disease.

This study describes the establishment of the multidisciplinary EGMON Clinic at the RVEEH and the clinical protocols and processes used in the clinic. The outcomes and the results of the patient survey on the effectiveness of the clinic are also discussed.

**Keywords:** glaucoma, shared-care, multidisciplinary clinics, orthoptists, optometrists, ophthalmic nurses

## INTRODUCTION

Glaucoma describes 'a group of ocular disorders with multi-factorial aetiology united by a clinically characteristic intraocular pressure-associated optic neuropathy'.<sup>1</sup> It constitutes the second leading cause of blindness in the world.<sup>2</sup>

An ageing population worldwide has resulted in an increase in the number of people over 65 years old, particularly in those 80 years or older.<sup>3</sup> One of the main risk factors for the development and progression of glaucoma is being over 65 years of age and it is estimated that one in ten Australians over 80 have glaucoma. The number of people worldwide with primary open angle glaucoma (POAG) and angle closure glaucoma (ACG) combined is expected to rise from 60.5 million in 2010 to 79.6 million by 2020, the majority of these (74%) having POAG.<sup>2</sup> In 2002 it was reported that 12% of world blindness is the result of glaucoma, with an even higher proportion in Australia at 18%.<sup>4</sup> Over 8.4 million people worldwide will be bilaterally blind from

primary glaucoma in 2010 rising to 11.1 million by 2020.<sup>2</sup> At least 50% of those with glaucoma are unaware that they have the disease.<sup>5</sup>

In Australia the prevalence of glaucoma is expected to increase from 208,000 in 2005 to 379,000 in 2025 due to the ageing population.<sup>5</sup> POAG is the most prevalent glaucoma subtype (70%)<sup>5</sup> and once diagnosed requires lifelong observation and management.<sup>6</sup> The annual cost of POAG alone in Australia in 2005 was \$1.9 billion and is expected to increase to \$4.3 billion by 2025.<sup>5</sup> The economic impact on health services will be enormous and limited healthcare resources will be increasingly overburdened.

Other factors identified that contribute to a rise in hospital glaucoma patient presentations are an increase in optometric case findings, raised public awareness and more aggressive management of ocular hypertension (OHT) and POAG cases.<sup>7</sup>

## SHARED-CARE GLAUCOMA SCHEMES

The increasing workload for glaucoma specialists and long waiting lists for appointments has necessitated the need for a more integrated team-based approach to patient care. The

Correspondence: **Debra Gleeson**  
Department of Diagnostic Eye Services (Orthoptics),  
The Royal Victorian Eye and Ear Hospital,  
32 Gisborne St, East Melbourne, Vic 3002, Australia  
Email: [debra.gleeson@eyeandear.org.au](mailto:debra.gleeson@eyeandear.org.au)



development of shared-care schemes involving optometrists and hospital-based eye care professionals including orthoptists, ophthalmic technicians and ophthalmic nurses are being introduced to meet these escalating service demands.

A shared-care screening service operating between the Rotterdam Eye Hospital and ten local optometrists trained by the hospital and provided with a GDx machine was initiated in 1999. Hospital-based ophthalmic technicians assess the optometrists' findings and electronically-submitted GDx data and recommend further tests at the hospital or follow-up by the optometrist. Ophthalmologists were available to provide advice.<sup>8</sup>

A similar project was set up by Portsmouth Hospital where the glaucoma specialist triaged the glaucoma referrals. Referrals were allocated to either a hospital appointment or were determined to be suitable for the refinement scheme, where patients would attend the community optometrist. Data sent by the community optometrist aided the hospital-based glaucoma specialist to determine whether the patient was discharged, given a hospital appointment or was monitored by the optometrist.<sup>9</sup> Another United Kingdom-based glaucoma referral refinement scheme was established in Manchester and involved optometrists referring glaucoma suspects to optometrists with specialised training. Patients that met the referral criteria were referred directly to the eye hospital and those that did not were referred back to the initial referring optometrist.<sup>10</sup> Both of these schemes endeavoured to reduce the number of false positive glaucoma suspect referrals to the hospital eye services.

Shared-care services are being widely utilised in the United Kingdom (UK). In 2006 a national UK study found that sixty-six ophthalmic departments were operating glaucoma based shared-care schemes.<sup>11</sup> The fourteen optometrist shared-care schemes were mainly community-based, whereas the fifty-two multidisciplinary schemes comprising optometrists, orthoptists and nurses were hospital-based. Ten of the schemes consisted of a team of optometrists, orthoptists and/or nurses. All the schemes managed both new and review glaucoma patients, and glaucoma suspects.<sup>11</sup>

In South Australia a shared-care service with authorised optometrists to co-manage glaucoma patients with an ophthalmologist commenced in 2008.<sup>12</sup>

The Bristol Shared Care Glaucoma Study found that optometrists with appropriate training were able to make reliable measurements in the assessment of glaucoma patients and glaucoma suspects.<sup>6,13,14</sup> There were no significant differences in patient outcomes over the two-year study period. However it was deemed unlikely to be more cost-effective than the hospital eye service with the annual cost per patient being £68.98 to £108.98 in community optometric shared-care compared to £14.50 to £59.95 under hospital care.<sup>6</sup> A 30-month randomised

clinical trial was conducted at the Rotterdam Eye Hospital comparing the costs and quality of care of stable glaucoma patients by optometrists and ophthalmic technicians with glaucoma specialists. The results showed that the quality of care was similar, and that despite a higher number of visits per year the mean hospital costs were lower by utilising the multidisciplinary team.<sup>15</sup>

## THE GLAUCOMA MONITORING CLINIC, THE ROYAL VICTORIAN EYE AND EAR HOSPITAL

The Glaucoma Monitoring Clinic (EGMON) at The Royal Victorian Eye and Ear Hospital (RVEEH) commenced in 2007. It is a multidisciplinary clinic set up to monitor chronic glaucoma patients. The current team comprises of four orthoptists, two optometrists and three ophthalmic nurses, a glaucoma fellow and one or two fellowship trained glaucoma specialists.

The practice guidelines followed by the team are those of the American Academy of Ophthalmology<sup>16</sup> and also of the Australian Government's National Health and Medical Research Council.<sup>17</sup> These guidelines present the current best evidence for the screening, diagnosis, management and prevention of glaucoma. A glaucoma clinical notes template is used and a standardised protocol is followed.

Patients are referred from the Glaucoma Investigation Research Unit (GIRU). All types of glaucoma patients are seen in the EGMON clinic, however they are less acute cases requiring three months or longer review times. The EGMON clinic also refers appropriate patients with physiological cupping, primary angle closure post laser peripheral iridotomy, glaucoma suspects and OHT cases to a community shared-care program of hospital-linked practitioners. The patients alternate their appointments between the hospital and these practitioners. There are predetermined protocols for referral back to the hospital.<sup>18</sup>

The optometrists, orthoptists and nurses do a full work-up on the patients. A comprehensive medical history to ascertain information relating to risk factors, systemic health, medications and other issues such as drug allergies that may affect progression or management is taken on each patient. The intraocular pressure is measured by Goldmann applanation tonometry and the central corneal thickness is recorded. In addition to the general slit-lamp examination performed by the orthoptist at the RVEEH, team members have learnt to conduct a structured anterior segment examination to identify the signs associated with glaucoma risk or presence, and other ocular problems.

Other skills performed at the slit-lamp include gonioscopy to assess the drainage angle and the use of an indirect lens to assess the optic disc and retina. These tests are fundamental parts of a comprehensive examination in glaucoma. These skills require a great deal of practice for proficiency, and to

become acquainted with the range of normal and abnormal presentations. In the 2006 UK shared-care schemes it was the optometrist who was the most likely clinician to perform disc and fundus assessment,<sup>11</sup> however in the EGMON clinic all team members perform these assessments.

A number of studies have identified that optometrists with appropriate training are able to make reliable measurements in assessing glaucoma patients and suspects.<sup>6,15,19</sup> At the time of writing this paper evidence of studies on the reliability of orthoptists or ophthalmic nurses' measurements in assessing glaucoma patients were not identified in the literature. The Grade 1 and 2 ophthalmic technicians working in the Rotterdam Eye Hospital Glaucoma Follow-up unit were not making optic disc assessments or performing gonioscopy.<sup>15</sup>

An internal clinical audit of the EGMON clinic in 2009–2010 of patient comorbidities showed that 20% had diabetes, 9% attended medical retinal clinic and 17% attended other specialist clinics, so to be able to recognise other ocular pathology such as diabetic retinopathy and macular degeneration is important when assessing the retina.

In diagnosing glaucoma and monitoring for progression, analysis of both structure (by optic disc and retinal nerve fibre layer assessment) and function (by visual field analysis) is essential. One or two members of the EGMON team perform Humphrey visual fields, visual acuity and subjective refraction if required. Ocular imaging by way of GDx nerve fibre analyser, Heidelberg retinal tomography, ocular coherence tomography and anterior segment ocular coherence tomography are all helpful tools for diagnosis and management. The ability to interpret these results is also an important part of the role of the multidisciplinary team. Patients are sent to the medical photography unit for these tests and for disc photos, which are mandatory for monitoring progression.

Once all the necessary assessments are completed the EGMON team members present the findings and suggested management plan to the consultant who makes the final clinical decision. In the UK shared-care schemes of 2006, optometrists, orthoptists and nurses in some schemes were making management decisions and in some cases prescribing medication.<sup>11</sup>

An integral function of this clinical model is ongoing staff training and development, with the first 30 minutes of each clinic devoted to teaching. Each week on a rotational basis, team members prepare presentations on glaucoma or related ocular or systemic topics, discuss research papers, journal reviews or case studies. Depression, which is common in those with chronic disease, low vision and the visual requirements for driving are amongst topics that have been discussed. Practical training in clinical skills is provided on a one-on-one basis during the clinic.

## EVALUATION

The EGMON clinic was set up in response to increasing numbers of patients attending the RVEEH glaucoma clinics, the largest tertiary glaucoma service in Victoria. The increase was impacting the availability of appointments for patient review. Six-month, nine-month and twelve-month review appointments were an average 29.1 weeks overdue. With the introduction of the EGMON clinic overdue review appointments have reduced to 3.3 weeks, helping to alleviate delays in monitoring and intervention. However there is still a large back-log of patients to be seen and the EGMON clinic has at this stage been unable to achieve its target of seeing 45 patients per session. The clinic is looking at ways to increase the numbers from the current template of 35 to 40 patients. Consultations in the EGMON clinic have increased the quality of care, enabling all patients to have a dilated examination each visit (unless contraindicated). All the necessary tests can be performed at the one visit eliminating the need for an extra appointment, which in turn opens up more appointment spaces.

In 2010 patients were given a questionnaire to assess their response to the new clinic. They were asked to rate the length of question time available to them during consultation and their waiting time in clinic. In regard to question and consultation time, 78% rated this as excellent or very good and 98% were happy with the waiting time. This concurs with the Bristol community optometrist shared-care scheme with 87% and 94% rating the same factors very satisfactory.<sup>13</sup> The EGMON clinic results showed that the patients' overall satisfaction with the service had increased from 50% in 2006–2007 to 84% in 2009–2010 rating the service excellent or very good. This was deemed to be due to the reduced waiting times in clinic and longer consultations. Other measures of success noted in a 2009–2010 audit were that 91% of patients had a dilated fundus examination and 91% had a recent gonioscopy recorded. This is in contrast with the snap-shot of UK shared-care schemes in 2006 where in 14 of the 30 schemes seeing new patients, a gonioscopy was not performed.<sup>11</sup> An internal audit conducted by the EGMON clinic showed greater than 90% adherence to the preferred practice patterns guidelines.<sup>16</sup>

## CONCLUSION

In offering a team-care approach to monitoring glaucoma the EGMON clinic has maximised and enhanced the skills of some of the existing hospital orthoptic and ophthalmic nurse workforce. The increased knowledge base has been useful in working on other clinics such as the general eye clinics, enabling the orthoptist to identify and present the relevant information, for example risk factors for glaucoma or glaucoma progression, changes in ocular or systemic

health, drug contraindications, and to organise the necessary tests to aid glaucoma management prior to the patient seeing the consultant.

One of the current EGMON orthoptists works on an orthoptically led glaucoma review clinic seeing less complex cases (glaucoma suspects and stable POAG) at Alfred Health.<sup>20</sup> This fortnightly clinic started as an off-shoot of the EGMON clinic in 2012. Patients are seen by the glaucoma specialist on alternate visits and these appointments are expedited if changes are noted following predetermined protocols. Due to its success, another EGMON clinic will commence at the RVEEH in late August 2013 staffed by one to two glaucoma consultants and four to five orthoptists.

Increased knowledge and enhancement of practical skills can only strengthen the role of the orthoptist in eye care. Orthoptists play a major role in outpatient collaborative care and so are well placed with their clinical knowledge and skills to take this step forward to aid in the provision of services to the increasing numbers of patients with chronic eye disease. Roles such as these will increase the viability and employment opportunity of orthoptists in a rapidly changing healthcare environment.

## ACKNOWLEDGEMENTS

I would like to thank Dr Cathy Green, Professor Jonathon Crowston, and all the previous and current glaucoma consultants and fellows who have worked on the EGMON clinic for their patience, guidance and instruction. Many thanks also to my multidisciplinary team mates, your help and pre-clinic teaching has been inspiring.

A big thank you to Linda Santamaria, your patience, guidance and invaluable assistance has been crucial in enabling me to produce my first article.

## REFERENCES

- Casson RJ, Chidlow G, Wood JP, et al. Definition of glaucoma: clinical and experimental studies. *Clin Experiment Ophthalmol* 2012;40(4):341-349.
- Quigley HA, Broman AT. The number of people with glaucoma worldwide in 2010 and 2020. *Br J Ophthalmol* 2006;90(3):262-267.
- Shaarawy TM, Sherwood MB, Hitchings RA, Crowston JG. *Glaucoma Volume 1: Medical Diagnosis & Therapy*. Philadelphia: Saunders Elsevier; 2009.
- Resnikoff S, Pascolini D, Etya'ale D et al. Global data on visual impairment in the year 2002. *Bull World Health Organ* 2004;82(11):844-851.
- Dirani M, Crowston JG, Taylor PS, et al. Economic impact of primary open-angle glaucoma in Australia. *Clin Experiment Ophthalmol* 2011;39(7):623-632.
- Gray SF, Spry PG, Brookes ST, et al. The Bristol shared care glaucoma study: outcome at follow up at 2 years. *Br J Ophthalmol* 2000;84(5):456-463.
- Morley AM, Murdoch I. The future of glaucoma clinics. *Br J Ophthalmol* 2006;90(5):640-645.
- de Mul M, de Bont AA, Reus NJ, et al. Improving the quality of eye care with tele-ophthalmology: shared-care glaucoma screening. *J Telemed Telecare* 2004;10(6):331-336.
- Trikha S, Macgregor C, Jeffery M, Kirwan J. The Portsmouth-based glaucoma refinement scheme: a role for virtual clinics in the future? *Eye (Lond)* 2012;26(10):1288-1294.
- Henson DB, Spencer AF, Harper R, Cadman EJ. Community refinement of glaucoma referrals. *Eye (Lond)* 2003;17(1):21-26.
- Vernon S A, Adair A; Shared care in glaucoma: a national study of secondary care lead schemes in England. *Eye (Lond)* 2010;24(2):265-269.
- Lu CY, Lu VH, Goldberg I, Day RO. Towards integrated care: Australia's new model of care for patients with glaucoma. *Med J Aust* 2010;193(4):200-201.
- Gray SF, Spencer IC, Spry PG, et al. The Bristol Shared Care Glaucoma Study: validity of measurements and patient satisfaction. *J Public Health Med* 1997;19(4):431-436.
- Spry PG, Spencer IC, Sparrow JM, et al. The Bristol Shared Care Glaucoma Study: reliability of community optometric and hospital eye service test measures. *Br J Ophthalmol* 1999;83(6):707-712.
- Holtzer-Goor KM, van Sprundel E, Lemij HG et al. Cost-effectiveness of monitoring glaucoma patients in shared care: an economic evaluation alongside a randomized controlled trial. *BMC Health Serv Res* 2010;10:312-322.
- American Academy of Ophthalmology. Preferred Practice Pattern Guidelines; 2010 [cited 2013 May 26th] Available from: <http://one.aao.org/CE/PracticeGuidelines/PPP.aspx>.
- Australian Governments National Health and Medical Research Council - Guidelines for the screening, prognosis, diagnosis, management and prevention of glaucoma; 2010. [cited 2013 May 26th] Available from: <http://www.nhmrc.gov.au/guidelines/publications/cp113-cp113b>.
- Clews S. The Royal Victorian Eye and Ear Hospital Community Eye Care Partnership. [cited 2013 May 26th] Available from: [www.aonavic.com.au/docs/presentation3.pdf](http://www.aonavic.com.au/docs/presentation3.pdf).
- Harper R, Reeves B, Smith G. Observer variability in optic disc assessment: implications for glaucoma shared care. *Ophthalmic Physiol Opt* 2000; 20(4):265-273.
- Thorburn D, Koklanis C. [Orthoptic-led glaucoma monitoring clinic at Alfred Health. Abstract from 69th Annual Orthoptic Scientific Conference 2012]. *Aust Orthopt J* 2012;44(2):26.



## A Case Report: Complicated Traumatic Hyphaema

**Khoi Khuat**, BHLthSc MOrth BBiomedSc<sup>1</sup>

**Elaina Dickeson**, BOrthGOphthSc BSc CertIVHlth(Nurs)<sup>2</sup>

<sup>1</sup> Department of Clinical Vision Sciences, La Trobe University, Melbourne, Australia

<sup>2</sup> Department of Ophthalmology, Alfred Hospital, Melbourne, Australia

### ABSTRACT

A 72-year-old male presented with a left traumatic hyphaema due to blunt trauma. Clinical examination found a 60% hyphaema and a mild increase in intraocular pressure. The hyphaema was slowly resolving with the patient suffering a secondary haemorrhage and a reduction in visual acuity. The patient was taking anticoagulant medication, which

predisposed him to developing a secondary haemorrhage. The secondary haemorrhage was surgically cleared but an improvement in visual acuity was not seen. A traumatic cataract was found upon slit lamp examination and was surgically removed resulting in an improvement in vision.

**Keywords:** traumatic hyphaema, blunt trauma, angle recession, traumatic cataract, anti-coagulants, intraocular pressure

### INTRODUCTION

**A** hyphaema is an accumulation of red blood cells within the anterior chamber.<sup>1</sup> Hyphaemas are generally caused by blunt or penetrating ocular trauma, but can also occur after surgery, spontaneously, or in patients who take anticoagulant medications that alter platelet and thrombin function such as aspirin and warfarin.<sup>1,2</sup>

Patients with hyphaemas often present with reduced vision or pain in the eye and a history of trauma.<sup>3</sup> Complications that can occur in hyphaema patients include elevated intraocular pressure, and secondary haemorrhage.<sup>2</sup> Elevated intraocular pressure is the most common complication of traumatic hyphaema and if left untreated it may result in clinical consequences such as glaucomatous optic neuropathy.<sup>4,5</sup> Thus, in order to prevent such consequences, accurate intraocular pressure readings are imperative.

A secondary haemorrhage is the second most common complication of traumatic hyphaema.<sup>4</sup> Predisposition to a secondary haemorrhage is linked to several factors with one of them being the use of anticoagulant medication, which prevent platelet aggregation and plug formation.<sup>6</sup>

Potential long-term complications include, late onset angle-recession glaucoma, late-onset traumatic cataract, and/or retinal detachment.<sup>4</sup> Studies have found that the extent of angle recession is directly correlated to an increase in risk of development of angle-recession glaucoma in the future.<sup>2,5,7</sup>

Therefore, in cases of traumatic hyphaemas caused by blunt trauma measurement of the extent of angle recession is helpful in determining potential risk.

### CASE REPORT

A 72-year-old male presented to the emergency department with a left hyphaema following blunt trauma to the eye. The right eye was unaffected and normal in appearance. The patient complained of reduced vision in the left eye with no pain or photopsia.

The patient had no significant past ocular history and was slightly myopic. His medical history revealed lung cancer and heart disease, including coronary stent surgery four years earlier. Hence it was noted that the patient's medications list included two anticoagulants acetylsalicylic acid (Aspirin) and clopidogrel bisulfate (Plavix).

Upon initial ocular examination no orbital bruising was seen around the left eye. Left visual acuity (VA) without correction was 6/24, improving to 6/18 with pinhole and right VA was 6/5. Slit lamp examination showed the left anterior chamber had a 60% hyphaema with 4+ red blood cells, the pupil was round and no epithelial defects were seen. TonoPen intraocular pressure (IOP) was 18mmHg in the right eye and 26mmHg in the left. Examination of the left fundus was not possible due to the presence of the hyphaema hence a B-scan was performed. There was no evidence of peripheral vascular disease, retinal detachment or vitreous haemorrhage.

The patient's diagnosis was a left hyphaema, caused by blunt trauma with a mild increase in IOP. Management

Correspondence: **Elaina Dickeson**  
Department of Ophthalmology, Alfred Hospital,  
55 Commercial Rd, Melbourne, VIC 3004, Australia  
Email: e.dickeson@alfred.org.au

included bed-rest with the patient's head elevated at 30 degrees. Prescription of gutte prednisolone acetate (Prednefrin Forte), gutte apraclonidine (Lopidine), gutte isopto homatropine (Homatropine) and acetazolamide (Diamox) tablets was instructed. In consultation with the patient's cardiologist, cessation of both anticoagulants was also advised. Review of the patient was to be the following day. However the patient did not return for review until five days after initial presentation.

At the first review appointment, the patient complained of intermittent discomfort in the left eye. He felt that the vision in the left eye had been improving, only to decrease the day before review, upon recommencing the anticoagulants. Left VA with correction was 6/60, with improvement on pinhole to 6/36. Left IOP obtained via iCare and Goldmann applanation was 30mmHg and 28mmHg respectively. Slit lamp examination of the left eye, showed a reduction in hyphaema size to 50%. The anterior chamber appeared deep and contained 4+ red blood cells.

The hyphaema at this visit was slowly improving. Management included continuing with the current eye drop regime with the addition of gutte brimonidine tartrate (Combigan). Cessation of the anticoagulants was also advised and the patient's cardiologist was contacted in regards to this issue. A review appointment was booked for the next day.

At the second review appointment (6 days post presentation) the patient's vision had decreased further, correcting to hand movements with no improvement on pinhole. Goldmann applanation IOP in the left eye was 27mmHg. Slit lamp examination showed that the hyphaema consisted of 20% free-floating red blood cells and 40% coagulated blood. Management included continuation of the current medication regime and cessation of the anticoagulants.

At the third review appointment (8 days post presentation) there was no change in vision. Left IOP via iCare and Goldmann applanation was 31mmHg and 32mmHg, respectively. Slit lamp examination showed a 60% deep hyphaema with 40% red blood cells, and the presence of microcysts within the anterior chamber. The hyphaema was not clearing but the IOP remained stable. The current medication regime was continued.

At the fourth review appointment (9 days post presentation) visual acuity remained unchanged. Left IOP via iCare and Goldmann applanation was 27mmHg and 29mmHg, respectively. Slit lamp examination showed superior iris debris, mild stromal staining and the presence of microcysts. As the hyphaema showed no signs of spontaneous resolution and the IOP remained elevated, an anterior chamber washout procedure was planned.

However, two days later the patient presented to the emergency department complaining of pain and loss of vision in left eye overnight. Left IOP via TonoPen was

48mmHg and slit lamp examination showed that the hyphaema covered the entire pupil. There was ++ corneal staining and 4+ red blood cells were seen in the anterior chamber. The patient suffered a secondary haemorrhage with an increase in IOP and an urgent anterior chamber washout procedure was done.

One day post anterior chamber washout, left VA remained unchanged and IOP via Goldmann applanation was 18mmHg. Slit lamp examination showed signs of corneal staining and the anterior chamber in the left eye was deeper than the right, containing 4+ inflammatory cells. The presence of a cataract was observed in the left eye as well as possible recession of the angle due to the trauma sustained.

One week after the procedure (18 days post presentation), left VA with correction was 6/60, improving with pinhole to 6/18. Left IOP via iCare was 5mmHg. Slit lamp examination showed the presence of corneal staining, and an anterior and posterior subcapsular cataract, with a grading of 2+ and 1+ respectively. No cyclodialysis cleft was observed and the optic disc was normal. The anterior chamber contained 2-3+ inflammatory cells. As improvement was evident isopto homatropine and brimonidine tartrate were ceased. Prednisolone acetate was continued but at a reduced frequency and the anticoagulants were also recommenced.

Two weeks after the procedure (25 days post presentation) left VA with correction was 6/36, improving with pinhole to 6/9. Left IOP via both iCare and Goldmann applanation was 13mmHg. Slit lamp examination showed a deep anterior chamber with 1+ inflammatory cells and no abnormalities were seen at the optic disc. Management included reducing prednisolone acetate and review was booked for one month's time.

At the next review appointment (55 days post presentation) it was decided that cataract surgery was needed to improve left VA. Pre-cataract operation, left VA with correction was 3/36, which improved with pinhole to 6/18. Post-cataract operation, left VA without correction was 6/18, which improved on pinhole to 6/9. The patient was to be reviewed in 6 months.

## DISCUSSION

Blunt trauma to the eye causes globe compression, which leads to an equatorial expansion of the globe.<sup>8</sup> This expansion places stress on anterior chamber structures, and a subsequent haemorrhage can result due to the rupturing of iris and/or ciliary body vessels.<sup>2</sup> Hyphaema absorption occurs via the trabecular meshwork pathway, where the erythrocytes leave the anterior chamber as intact and undamaged cells. Uncomplicated hyphaemas generally resolve within one week from initial presentation.<sup>2</sup> However, in this case the patient's hyphaema did not resolve

However, in this case the patient's hyphaema did not resolve within one week and a secondary haemorrhage occurred.

The most common resultant complication of traumatic hyphaema is elevated intraocular pressure (IOP).<sup>4</sup> The term intraocular pressure can be described as the amount of tension utilised by the aqueous humour within the intraocular tissues in response to the balance between its production and drainage.<sup>9</sup> Elevated IOP was seen at initial presentation and continued to be elevated at each review appointment. The increase in IOP occurs as a result of obstruction of the trabecular meshwork from red blood cells, fibrin and platelets or from direct damage to the outflow pathways.<sup>10</sup> If elevated IOP is left untreated it may further result in clinical consequences such as glaucomatous optic neuropathy, acute retinal arteriolar occlusion or corneal bloodstaining.<sup>5</sup>

To prevent these clinical consequences, accurate IOP measurement is imperative. The most common commercially available tonometers used for IOP measurement are based on corneal indentation/applanation principles.<sup>9</sup> The tonometry devices utilised in this case were the iCare, TonoPen and Goldmann Applanation Tonometer (GAT). The GAT device is the current gold standard for IOP measurements because it has been shown to have less variation in repeated IOP measurements.<sup>11,12</sup> The accuracy of GAT however, is influenced by corneal thickness, curvature and biomechanical factors, with these factors being highly variable among individuals.<sup>13</sup> In patients with thin corneas (<525 $\mu\text{m}$ ) GAT underestimates IOP and in thicker corneas (>555 $\mu\text{m}$ ) GAT overestimates IOP.<sup>9</sup>

Studies have found that iCare IOP measurements are also influenced by central corneal thickness (CCT).<sup>14</sup> When compared to GAT, iCare overestimated IOP at higher CCTs and underestimated at lower CCTs.<sup>14</sup> Overall, iCare would be practical for screening purposes but if used clinically, CCT should always be considered in addition to the measurement.<sup>9</sup> When compared to GAT, the TonoPen was similar to GAT in that the device showed a weak statistically significant correlation with CCT values.<sup>15</sup> This device also underestimated IOP in thinner corneas and overestimated in thicker corneas.<sup>15</sup> Therefore, TonoPen measurements should be interpreted cautiously, especially in eyes with thick corneas.<sup>9</sup>

Among all the commercially available tonometers, no device has been found to give accurate IOP measurement regardless of CCT.<sup>9</sup> Therefore, rather than using multiple devices on a patient as within this case report, clinicians should choose the tonometer best suited to the clinical indication and use it consistently during clinical follow up.<sup>9</sup> Consistent use of the same tonometer is just as important as the choice of tonometer itself.<sup>16</sup>

After elevated IOP, the second most common complication of traumatic hyphaema is a secondary haemorrhage.<sup>4</sup> As previously mentioned, the patient's hyphaema did not

resolve within one week and a secondary haemorrhage occurred. A secondary haemorrhage often occurs within the first five days of the initial bleed and occurs as a result of retraction and lysis of the clot, which had occluded the initial damaged vessel.<sup>1,6</sup> In this case, the patient suffered a secondary haemorrhage approximately 13 days after initial presentation with an associated increase in IOP. Factors which predispose a patient to a secondary haemorrhage include a presenting VA of 6/60 or worse, an initial hyphaema volume of more than one-third of the anterior chamber, the use of salicylates or other anticoagulating drugs, positive sickle cell anaemia and delayed seeking of medical attention (greater than 24 hours).<sup>6</sup>

Aspirin (acetylsalicylic acid) is an anticoagulant, which has an inhibitory effect on the blood clotting mechanism of the body.<sup>17</sup> It prevents platelet aggregation and plug formation, which results in a prolonged bleeding time.<sup>17</sup> A study conducted by Crawford et al<sup>17</sup> concluded that the incidence of secondary haemorrhages increased with the administration of aspirin. Thus this drug would be contraindicated in conditions where clot formation is needed to enable resolution, such as the presence of a traumatic hyphaema. Recchia et al<sup>8</sup> recommended restriction of these drugs for two weeks after a traumatic hyphaema unless necessary for a medical condition. The patient was taking both salicylates and antiplatelet drugs for management of his cardiac condition, so it was critical to cease these to prevent a secondary haemorrhage. However, as it is important not to impact upon the patient's cardiovascular health, the cardiologist is best involved in the management process.

Surgical management of the patient's secondary haemorrhage was an anterior chamber washout to clear the haemorrhage and reduce IOP.<sup>6</sup> The procedure has minimal surgical complications and involves washing out the erythrocytes from the anterior chamber clot, leaving behind the fibrin matrix.<sup>6</sup> Post anterior chamber washout the patient's IOP was successfully reduced but left VA remained poor.

A secondary haemorrhage is generally more severe than the initial hyphaema and is thought to be associated with a poor visual prognosis.<sup>1,18</sup> However a retrospective study conducted by Cho et al<sup>10</sup> concluded that a secondary haemorrhage does not result in a poor visual outcome. The severity of the trauma and the associated ocular injuries, especially posterior segment injuries were found to result in a poor visual outcome.

A final visual acuity of less than 6/9 has been found to be associated with macular hole, traumatic cataract and macular degeneration.<sup>6</sup> In this case a traumatic cataract was detected on slit lamp examination and this was deemed the cause of the reduced VA. Cataract formation may occur as an early or late complication of ocular trauma. Trauma-related lens abnormality results from either a loss of transparency



or loss of positioning.<sup>19</sup> The patient had left cataract surgery and post operation VA subsequently improved.

Possible angle recession was also noted on slit lamp examination. Patients with angle recession are at a higher risk of developing secondary glaucoma later on in life and often require long term monitoring to prevent irreversible optic nerve damage.<sup>7,8</sup> The extent of angle recession has been found to directly correlate with an increased risk of developing a secondary glaucoma, particularly if the angle is recessed more than 180 degrees.<sup>2</sup> One prospective study found that the early predictors of traumatic glaucoma following blunt trauma were heavy trabecular meshwork pigmentation, an elevated baseline IOP, hyphaema, angle recession and lens displacement with a cataract,<sup>7</sup> with most of these factors being present in this case. There was no exact measurement taken of the extent of angle recession seen in the patient, so in hindsight this information would be useful in determining the relative risk of the patient developing a secondary glaucoma in the future.

## CONCLUSION

An uncomplicated traumatic hyphaema generally resolves within a week of the initial presentation. In this report, the patient's hyphaema did not spontaneously resolve and a secondary haemorrhage occurred. This was likely associated with the patient's use of salicylates and antiplatelet drugs taken for management of his cardiac condition. Therefore it is critical to cease these drugs to prevent complications such as a secondary haemorrhage. However, this results in a clinical dilemma, as cessation of the drugs may impact negatively upon the patient's cardiovascular health. Thus liaison between the ophthalmologist and cardiologist would be vital in the management of these cases of traumatic hyphaema.

In this report the secondary haemorrhage was managed via an anterior chamber washout, which did not improve vision. This reduction in vision was due to the development of a traumatic cataract, as vision improved after cataract surgery was performed.

Elevation in intraocular pressure is another complication of a traumatic hyphaema. If this is not effectively managed numerous clinical consequences may occur. In order to prevent these clinical consequences accurate IOP measurement is imperative. Therefore, rather than using multiple devices on a patient as in this case report, it is recommended that clinicians choose and consistently utilise at each review appointment, a tonometer best suited to the clinical condition. By doing so the accuracy of results would be maintained, thus ensuring that there are no contradictory measurements, ultimately ensuring appropriate patient management.

A factor that should also be taken into account in cases

with blunt trauma is angle recession. This should not be overlooked because angle recession is directly correlated with an increased risk of development of a secondary glaucoma, especially if the extent of recession is more than 180 degrees. Therefore information about the extent of angle recession would be useful in determining the patient's relative risk of developing a secondary glaucoma in the future.

## ACKNOWLEDGEMENTS

The authors would like to acknowledge and thank Linda Santamaria for her support and assistance.

## REFERENCES

1. Bausback HJ. Clinical management of hyphema. *Clin Eye Vis Care* 1995;7(2):83-90.
2. Walton W, Von Hagen S, Grigorian R, Zarbin M. Management of traumatic hyphema. *Surv Ophthalmol* 2002;47(4):297-334.
3. Sankar PS, Chen TC, Grosskreutz CL, Pasquale LR. Traumatic hyphaema. *Int Ophthalmol Clin* 2002;42(3):57-68.
4. Shiuey Y, Lucarelli MJ. Traumatic hyphema: outcomes of outpatient management. *Ophthalmology* 1998;105(5):851-855.
5. Gottsch JD. Hyphema: diagnosis and management. *Retina* 1990;10(Suppl1):S65-S71.
6. Crouch ER Jr, Crouch ER. Management of traumatic hyphema: therapeutic options. *J Pediatr Ophthalmol Strabismus* 1999;36(5):238-250.
7. Sihota R, Kumar S, Gupta V, et al. Early predictors of traumatic glaucoma after closed globe injury: trabecular pigmentation, widened angle recess, and higher baseline intraocular pressure. *Arch Ophthalmol* 2008;126(7):921-926.
8. Recchia FM, Saluja RK, Hammel K, Jeffers JB. Outpatient management of traumatic microhyphema. *Ophthalmology* 2002;109(8):1465-1470.
9. De Moraes CGV, Prata TS, Liebmann J, Ritch R. Modalities of tonometry and their accuracy with respect to corneal thickness and irregularities. *J Optom* 2008;1(2):43-49.
10. Cho J, Jun BK, Lee YJ, Uhm KB. Factors associated with the poor final visual outcome after traumatic hyphema. *Korean J Ophthalmol* 1998;12(2):122-129.
11. Van der Jagt LH, Jansonius NM. Three portable tonometers, the TGDc-01, the iCare and the Tonopen XL, compared with each other and with Goldmann applanation tonometry. *Ophthalmic Physiol Opt* 2005;25(5):429-435.
12. Fernandes P, Diaz-Rey JA, Queiros A, et al. Comparison of iCare rebound tonometer with the Goldmann tonometer in a normal population. *Ophthalmic Physiol Opt* 2005;25(5):436-440.
13. Salvat ML, Zeppieri M, Milani F, et al. Comparison of iCare tonometer and Goldmann applanation tonometry in normal corneas and in eyes with automated lamellar and penetrating keratoplasty. *Eye (Lond)* 2011;25(5):642-650.
14. Nakamura M, Darhad U, Tatsumi Y, et al. Agreement of rebound tonometer in measuring intraocular pressure with three types of applanation tonometers. *Am J Ophthalmol* 2006;142(2):332-334.
15. Salvat ML, Zeppieri M, Tosoni C, Brusini P. Comparisons between Pascal dynamic contour tonometry, the TonoPen, and Goldmann applanation tonometry in patients with glaucoma. *Acta Ophthalmol Scand* 2007;85(3):272-279.

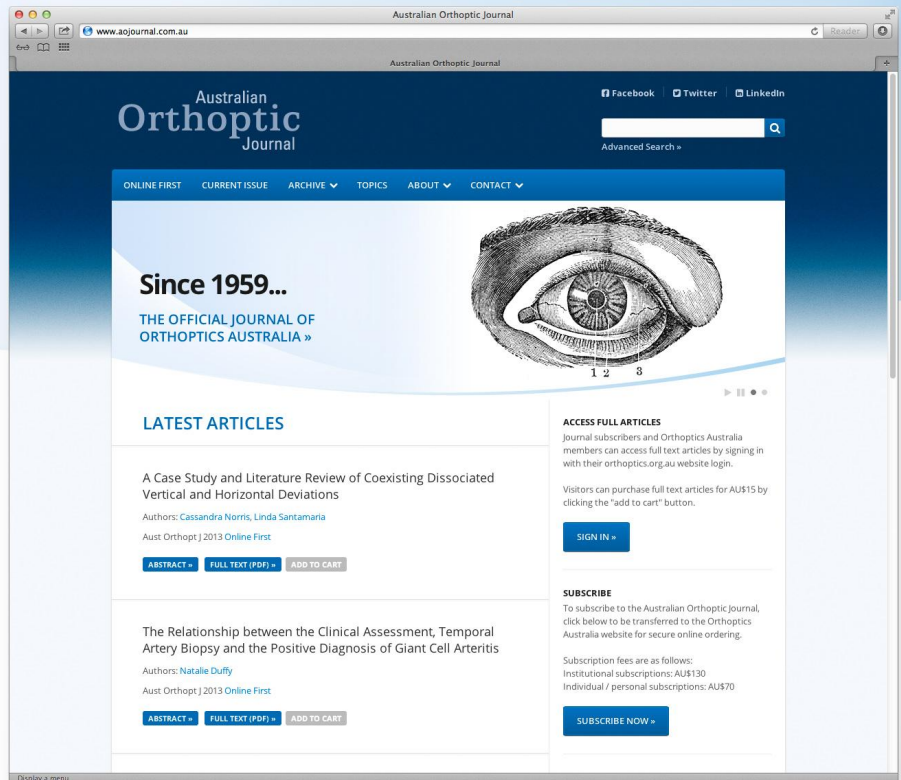
16. Cook JA, Botello AP, Elders A, et al. Systematic review of the agreement of tonometers with Goldmann applanation tonometry. *Ophthalmology* 2012;119(8):1552-1557.
17. Crawford JS. The effect of aspirin on rebleeding in traumatic hyphema. *Trans Am Ophthalmol Soc* 1975;74:356-362.
18. Edwards WC, Layden WE. Traumatic hyphaema. A report of 184 consecutive cases. *Am J Ophthalmol* 1973;75(1):110-116.
19. Lacmanovic Loncar V, Petric I. Surgical treatment, clinical outcomes, and complications of traumatic cataract: retrospective study. *Croat Med J* 2004;45(3):310-313.

# aojournal.com.au

THE JOURNAL NOW ONLINE...

Featuring:

- **Online First** – read the latest articles before they are published to print
- **Current Issue** – as well as an archive of previous issues
- **Full Articles** – freely accessible to OA members and AOJ subscribers
- **Abstracts** – for public access and full text PDFs for purchase
- **Advanced Searching** – search by author, title, keywords and more
- **Article Alerts** – receive an email as soon as a new article is posted
- **Sign in** – with your OA Site login



## Charles Bonnet Visual Hallucinations in Children: A Systematic Review

Meri Vukicevic, PhD  
Stuart Keel, BOrth&OphthSc(Hons)

Department of Clinical Vision Sciences, La Trobe University, Melbourne, Australia

### ABSTRACT

Visual pathway lesions are known to cause visual hallucinations and when they are complex, are described as Charles Bonnet syndrome (CBS). CBS hallucinations are common in adults and prevalence rates may be up to 40%. Very little is known about the prevalence and characteristics of CBS in children. If the postulated theories as to the cause

of CBS are correct, 'sensory deprivation' or 'release', then it stands to reason that children also suffer from this disorder. A systematic review was conducted to identify reports of CBS in children and compare the findings to that reported in the literature concerning adults.

**Keywords:** visual hallucinations, Charles Bonnet syndrome, vision impairment, children

### INTRODUCTION

Visual hallucinations are defined as perception of visual objects in the absence of external stimuli, that is, when a person claims or acts as if they can see something or someone that other observers cannot see.<sup>1</sup> Possible causes of visual hallucinations include neurological or psychiatric disorders, ophthalmic disease, hypnosis or intense emotional experiences, drugs or alcohol and even sleep deprivation.<sup>1,2</sup> Charles Bonnet syndrome (CBS) is a common condition characterised by visual hallucinations that result from various kinds of lesions along the visual pathway, from cornea to occipital lobe.<sup>3</sup> CBS hallucinations are characterised by recurrent elaborate visual hallucinations in people with clear consciousness, preserved intellectual functioning and insight that the hallucination is not real.<sup>4,5</sup> CBS has been well documented in older persons and is known to be associated with vision impairment. The prevalence of the disorder varies from 0.4 to 40% with lower prevalence in Asian populations. The vastly different prevalence rates may be due to a high non-reporting of hallucinations as patients are reluctant to discuss their symptoms due to the association of hallucinations with the onset of a psychiatric disorder.<sup>6-12</sup>

Whilst CBS most commonly presents in patients with age-related macular degeneration, it can occur with any ocular pathology. Onset is associated with anomaly in any area of the visual pathway and may not always present in patients with decreased visual acuity.<sup>12</sup> Two theories as to the cause

of CBS have been postulated: the 'release' and the 'sensory deprivation' theories. These theories have been well described in the literature<sup>4,13,14</sup> and both relate to defective electrochemical impulses in the visual system. The 'release' theory suggests that these defective impulses are a result of lesions along the visual pathway. The 'sensory deprivation' theory on the other hand, postulates that it is deprivation of a visual stimulus secondary to ocular pathology that causes the defective impulses.

The complexity of CBS hallucinations means that patients report images of people, animals, trees, cars, buildings and kaleidoscope patterns and this complexity differentiates them from simple floaters or photopsia.<sup>4,14,15</sup> Hallucinations most commonly occur weekly and last for several minutes. Sufferers are not often aware of the triggers nor are they able to make the hallucinations stop. Often the hallucinations evoke a negative emotional response, namely in the way of stress as patients are concerned as to the cause of the symptoms.<sup>12</sup> To date there is no effective treatment for CBS.<sup>16-20</sup>

CBS is most common in elderly patients with vision impairment. However, the causal theories suggest that it is possible that these types of hallucinations could affect any age group with pathology along the visual pathway, inclusive of children. The presentation and characteristics of CBS have not been well defined in children and diagnosis of the disorder can be confused with childhood imaginings, difficulty identifying or describing the symptoms or with other conditions including epilepsy or psychosis. The aim of this systematic review was to identify reports of CBS in children and summarise the findings, comparing the presentation of CBS in children to that found in adults.

Correspondence: **Dr Meri Vukicevic**  
Department of Clinical Vision Sciences,  
La Trobe University, VIC 3086, Australia  
Email: m.vukicevic@latrobe.edu.au



**METHODS**

**INFORMATION SOURCES AND SEARCH STRATEGY**

A systematic Medline, EMBASE and PubMed search of relevant articles was conducted with coverage up to February 18, 2013. Search terms were pilot tested for accuracy and modified until a final search strategy could be used to achieve the desired outcome using all three databases. All searches included a combination of the keywords: child\*, paediatric\*, Charles Bonnet and visual hallucination\*. The search was not restricted by date but was limited to studies conducted in the English language. The reference lists of retrieved articles were utilised to identify additional resources.

**STUDY SELECTION**

Two reviewers (MV & SK) independently searched the three databases and screened the resultant titles and abstracts. Articles were systematically excluded if the title and abstract were not relevant and full text manuscripts were obtained for all studies that were potentially relevant.

**ELIGIBILITY AND EXCLUSION CRITERIA**

Prospective, retrospective, cohort, case-control and cross-sectional studies were eligible for inclusion in the review. Studies that involved children or adolescents up the age of 18 years who were experiencing visual hallucinations characteristic of that which is seen in CBS were included. Studies that involved hallucinations in any other sensory modality, such as auditory, tactile and, olfactory, were not eligible. CBS associated with adults, children with a psychiatric/psychological diagnosis or confounding general health issues including epilepsy and seizures or drug induced hallucinations were also ineligible for inclusion. Review articles reported as abstracts were excluded.

**RESULTS**

After combining all searches, 1,146 abstracts were identified and screened. Of these 30 were considered potentially relevant and full articles were retrieved for further evaluation. Twenty-four of these studies did not meet the inclusion/exclusion criteria, leaving six studies to be included in the review. Of the excluded studies, 10 were related to psychiatric hallucinations, three were not Charles Bonnet Syndrome, two were conducted on individuals over the age of 18 years, one was related to auditory hallucinations, and one was related to epileptic hallucinations. There was complete agreement between the reviewers for eligibility. A meta-analysis was not performed due to the small number of articles. Figure 1 depicts the study selection process.

Single case reports of seven children, all male, aged 4 to

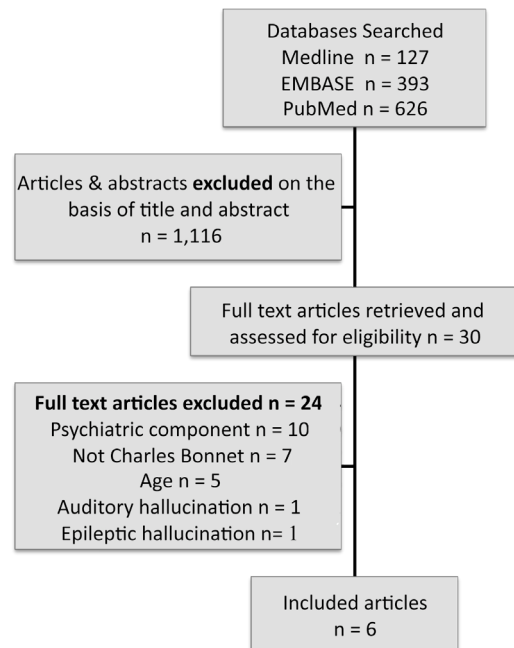


Figure 1. Flowchart of study selection process.

11 years were found across six articles published from 1974 to 2012 in Australia, Canada, United States, Belgium and Turkey. A summary of each case is shown in Table 1. Six boys had severe vision impairment and one had a visual field defect in his left lower quadrant. Two boys were diagnosed with cone-rod dystrophy and a third had symptoms consistent with this diagnosis, although the authors did not confirm this. The visual diagnosis for three boys was a compressive lesion and one boy had retro-bulbar optic neuritis secondary to herpes encephalitis.

The type of images experienced by these children included people (both familiar and unfamiliar), animals, Santa Claus, a ballerina, insects/reptiles, houses, cars, a prisoner behind bars and little alien-like people with horns. Information about the children’s insight into the unreal nature of the hallucination, frequency and duration of hallucinations, triggers, associated emotions and ability to control the images is sporadically reported, with most of this information unknown. There is no information contained in the case reports about exactly how the visual hallucination was reported by these children, whether they volunteered this information to their parents or if it was found upon questioning by an ophthalmologist/neurologist.

**DISCUSSION**

Almost 40 years of literature has yielded only seven case reports of CBS in children and surprisingly all reports describe male children. CBS in adults more commonly occurs in females and this reflects the demographic of the patients who have vision impairment in this age group.<sup>12</sup> The fact that all the children in these case reports were

Table 1. Summary of case reports

Year	Authors	Location	Age	Sex	VA	Diagnosis	General Health	Images	Insight	Frequency/ duration	Emotion, triggers, ability to control
1974	Lance, Cooper & Misbach <sup>21</sup>	Sydney Australia	11	Male	VF defect: incongruent left inferior quadrantanopia	Glioma		Prisoner behind bars, little people with horns like aliens		4 times per day for 30 sec	
1992	White & Jan <sup>22</sup>	Vancouver Canada	4	Male	NPL R & L	Optic nerve glioma	Suprasellar tumour dx age 11 months	People, animals, familiar objects, Santa Claus	Angry when told they were imaginary	Lasted 3 days	Initially frightened, no auditory, olfactory or tactile components, ceased when asleep
1993	Lanska & Lanska <sup>23</sup>	Kentucky USA	8	Male	PL both eyes	Pale discs, attenuated vessels, no ERG response	Presented age 5 (normal), vision loss by age 8, and spasticity, inattention & motor dysfunction by age 11	Family members, girls, faces, cars, lights	No insight, thought they were real	Intermittent	
1998	Schwartz & Vahgej <sup>24</sup>	West Virginia USA	6	Male	R HM L CF	Pale discs, attenuated vessels, mildly constricted VF, cone-rod dystrophy	No meds, no medical or psych illness	Ballerina, distorted lines, flashes, people, houses		Constant	Frightened by the ballerina, worse at night, couldn't make them disappear
			10	Male	R 6/240 L 6/120	Pigment disturbance, attenuated arterioles, cone-rod dystrophy	No meds, no medical or psych illness	Floating coloured balls, unfamiliar people, snowballs with faces, wolves, people falling off a cliff			Increased with stress, fatigue or boredom, no voluntary control, continued with eye closure, stopped with sleep
2002	Mewasingh et al <sup>25</sup>	Brussels Belgium	7	Male	R 1/60 L NPL	VF constricted to 20 deg, cranio-pharyngioma removed age 7, CNIII palsy, bilateral optic disc atrophy	Growth failure, obesity	Scorpions, reptiles, mammals	Preserved	2 times per week for 15-20 mins	Frightened at first, then found them interesting, mostly occurred upon waking
2012	Aydin et al <sup>26</sup>	Samsun Turkey	4	Male	BE CF@1m	Retrolubar ON secondary to herpes encephalitis	HSV in cerebrospinal fluid	Unfamiliar child		2-3 times per day for 2-5 mins	Occurred when eyes open & awake

male most likely reflects the small sample size rather than a correlation between gender and CBS.

Whilst there were only seven case reports found, the condition is probably more common than we realise, especially in children with vision impairment. If the postulated theories as to the cause of CBS are correct, ie the 'release' or 'sensory deprivation' theories, then it stands to reason that children with vision impairment or a lesion at any level of the visual pathway would experience these hallucinations just as adults do. This is consistent with the reported visual acuity of these children; all but one had poor visual acuity suggesting a sensory deprivation cause, and the child with better vision had a compressive glioma, suggesting the abnormal release factor. The difficulty arises in diagnosing the disorder. Varying opinions in the current literature exist with some researchers suggesting that these complex hallucinations could simply be normal childhood imaginings, while others believe they are indicative of more

serious conditions such as underlying psychosis or epilepsy. At present, agencies providing services to the vision impaired in Australia do not address the issue of CBS in terms of diagnosis nor do they offer solutions about how to deal with the hallucinations to the children or their carers.

The characteristics of the hallucinations reported by the children in these seven case studies are very similar to those reported in adults. Images of people (both familiar and unfamiliar) were seen by six of the seven boys and images of people are most commonly seen by adults with CBS. The frequency and duration of the hallucinations was also similar in that it varied greatly, from twice a week to being constantly present and lasting for 30 seconds and longer.<sup>4,5,12</sup> Ability to control the hallucination was reported in three papers and no child was able to make the symptoms disappear. Ability to control or make CBS hallucinations disappear is not widely documented in CBS studies in adults, and where it is, ability for control seems

inconsistent and is person-dependent.<sup>5,7,12</sup> There has also been no reported correlation between ability for control and either causative theory.

Three case reports included information about the child's insight into the unreal nature of the hallucination they were experiencing. Two boys (aged 4 and 8) thought the hallucinations were real whilst one (aged 7) was aware that they were not. This is in contrast with CBS reports in adults where insight is preserved by almost all sufferers, except on occasions where the person is seeing ordinary objects that fit realistically into their surroundings.<sup>3</sup> Furthermore, none of the reviewed cases displayed any identifiable anterior (corneal) lesions that have been associated with CBS in adults. The very small number of reported cases of children with CBS and the fact that they might be too young for insight could account for this difference compared with CBS in adults.

In light of the reported prevalence rates in some adult populations being around 40% and that the complexity and nature of CBS hallucinations in children are very similar to those reported in adults, clinicians working with vision impaired children should be vigilant in identifying CBS. Documenting the characteristics of CBS hallucinations can be useful for differentiating this disorder from those previously mentioned and parents should be educated to be aware of this possibility, despite the fact that treatment does not exist.

## CONCLUSION

This systematic literature review has confirmed that Charles Bonnet syndrome can indeed occur in children, yet there is still much to discover about the presentation and characteristics of these hallucinations in young populations. Replication of the studies conducted in adults with CBS on younger children would most certainly reveal some of the mysteries of the prevalence and features of the disorder in this population and would confirm whether in fact male children are more predisposed to CBS.

## REFERENCES

- Cummings JL, Miller BL. Visual hallucinations: clinical occurrence and use in differential diagnosis. *West J Med* 1987;146(1):46-51.
- Schultz G, Melzack R. The Charles Bonnet syndrome: 'phantom visual images'. *Perception* 1991;20(6):809-825.
- De Morsier G. The Charles Bonnet syndrome: visual hallucinations in the aged without mental deficiency. *Annales Medico-Psychologiques* 1967;2(5):678-702.
- Mogk LG, Riddering A, Dahl D, et al. Charles Bonnet syndrome in adults with visual impairments from age-related macular degeneration. In: Stuen C, Arditi A, Horowitz A, et al, editors. *Vision Rehabilitation: Assessment, Intervention and Outcomes*. Downingtown: Swets & Zeitlinger; 2000. p. 117-119.
- Teunisse RJ, Zitman FG, Raes DCM. Clinical evaluation of 14 patients with the Charles Bonnet syndrome (Isolated visual hallucinations). *Compr Psychiatry* 1994;35(1):70-75.
- Abbott EJ, Connor GB, Artes PH, Abadi RV. Visual Loss and visual hallucinations in patients with age-related macular degeneration (Charles Bonnet syndrome). *Invest Ophthalmol Vis Sci* 2007;48(3):1416-1423.
- Holroyd S, Rabins PV, Finkelstein D, et al. Visual hallucinations in patients with macular degeneration. *Am J Psychiatry* 1992;149(12):1701-1706.
- Hou Y, Zhang Y. The prevalence and clinical characteristics of Charles Bonnet syndrome in Chinese patients. *Gen Hosp Psychiatry* 2012;34(5):566-570.
- Jackson ML, Bassett K, Nirmalan PV, Sayre EC. Contrast sensitivity and visual hallucinations in patients referred to a low vision rehabilitation clinic. *Br J Ophthalmol* 2007;91(3):296-298.
- Singh A, Sorensen TL. The prevalence and clinical characteristics of Charles Bonnet syndrome in Danish patients with neovascular age-related macular degeneration. *Acta Ophthalmol* 2012;90(5):476-480.
- Teunisse RJ, Cruysberg JR, Verbeek AL, Zitman FG. The Charles Bonnet syndrome: A large prospective study in The Netherlands. A study of the prevalence of the Charles Bonnet syndrome and associated factors in 500 patients attending the University Department of Ophthalmology at Nijmegen. *Br J Psychiatry* 1995;166(2):254-257.
- Vukicevic M, Fitzmaurice K. Butterflies and black lacy patterns: the prevalence and characteristics of Charles Bonnet hallucinations in an Australian population. *Clin Experiment Ophthalmol* 2008;36(7):659-665.
- Manford M, Andermann F. Complex visual hallucinations: clinical and neurobiological insights. *Brain* 1998;121(Pt10):1819-1840.
- Pliskin NH, Kiolbasa TA, Towle VL, et al. Charles Bonnet Syndrome: an early marker for dementia? *J Am Geriatr Soc* 1996;44(9):1055-1061.
- Teunisse RJ. Charles Bonnet syndrome, insight and cognitive impairment. *J Am Geriatr Soc* 1997;45(7):892-893.
- Coletti Moja M, Milano E, Gasverde S, et al. Olanzapine therapy in hallucinatory visions related to Bonnet syndrome. *Neurol Sci* 2005;26(3):168-170.
- Hori H, Terao T, Shiraishi Y, Nakamura J. Treatment of Charles Bonnet syndrome with valproate. *Int Clin Psychopharmacol* 2000;15(2):117-119.
- Lang UE, Stogowski D, Schulze D, et al. Charles Bonnet syndrome: successful treatment of visual hallucinations due to vision loss with selective serotonin reuptake inhibitors. *J Psychopharmacol* 2007;21(5):553-555.
- Razavi M, Jones RD, Manzel K, et al. Steroid-responsive Charles Bonnet syndrome in temporal arteritis. *J Neuropsychiatry Clin Neurosci* 2004;16(4):505-508.
- Ukai S, Yamamoto M, Tanaka M, Takeda M. Treatment of typical Charles Bonnet syndrome with donepezil. *Int Clin Psychopharmacol* 2004;19(6):355-357.
- Lance JW, Cooper B, Misbach J. Visual hallucinations as a symptom of right parieto-occipital lesions. *Proc Aust Assoc Neurol* 1974;11:209-217.
- White CP, Jan JE. Visual hallucinations after acute visual loss in a young child. *Dev Med Child Neurol* 1992;34(3):259-261.
- Lanska DJ, Lanska MJ. Visual 'release' hallucinations in juvenile neuronal ceroid-lipofuscinosis. *Pediatr Neurol* 1993;9(4):316-317.
- Schwartz TL, Vahgei L. Charles Bonnet syndrome in children. *J AAPOS* 1998;2(5):310-313.
- Mewasingh LD, Kornreich C, Christiaens F, et al. Pediatric phantom vision (Charles Bonnet) syndrome. *Pediatr Neurol* 2002;26(2):143-145.
- Aydin OF, Ince H, Tasdemir HA, Ozyurek H. Charles Bonnet syndrome after herpes simplex encephalitis. *Pediatr Neurol* 2012;46(4):250-252.

## Selected Abstracts from the Orthoptics Australia 70th Annual Scientific Conference held in Hobart 3 to 6 November 2013

### PATRICIA LANCE LECTURE FINDING THE LEADER WITHIN

**Sue Silveira**

The Patricia Lance Lecture was presented by Sue Silveira at the 70th Annual Scientific Conference, Hobart, November 2013. Patricia Lance was recognised for her contribution to the profession of Orthoptics, with brief details of her professional career and achievements provided. The lecture outlined the changes to the educational program in NSW, including the closure of the Discipline of Orthoptics, Faculty of Health Science, University of Sydney, the establishment of Orthoptics Australia Tertiary Education Working Party and the activities this working party has undertaken in 2013 to secure a new educational program for Orthoptics in NSW.

Key findings regarding the professional orthoptic workforce which have been used in submissions to universities were presented. The need for continued leadership within the profession of Orthoptics was also discussed, with members asked to 'find the leader within'.

### LASER CATARACTS

**Sabrina D'Avino Sagar**

'Laser cataracts' is a new and exciting technology with only seven Alcon Lens Sx machines in New South Wales. The presentation described the procedure, the benefits of laser cataract surgery, the orthoptist's role with the Laser Sx and some results.

### ABNORMAL HEAD POSTURES IN CHILDREN

**Jodie Attard, Priya Naryan**

The presence of an abnormal head posture (AHP) is a significant finding in an orthoptic assessment. The impact of the AHP needs to be considered during the course of the assessment as thorough assessment may give diagnostic clues and could impact the patient's management plan. This presentation gave an overview of the incidence and causes of abnormal head postures in children, both ocular and non-ocular causes, with focus on the ocular reasons and benefits of adopting an AHP.

### CORNEAL CROSS-LINKING: OUTCOMES IN THE TREATMENT OF KERATOCONUS

**Ana Alexandratos**

Keratoconus is a degenerative condition of the cornea which causes distortion and buckling. The thinning and bulging of corneal tissue is a result of weakened collagen bonds. Corneal cross-linking has been used to treat mild to moderate forms of keratoconus, but how effective is it?

This presentation looked at a group of patients undergoing this treatment and evaluated the outcomes using Pentacam imaging with discussion of the limits of this treatment, and when a corneal graft is the only treatment option.

### THE ACCURACY OF ORTHOPTISTS IN INTERPRETING MACULAR OCT IMAGES

**Jess Boyle, Yong Ern Lim, Meri Vukicevic, Connie Koklanis**

Age-related macular degeneration (AMD) is the leading cause of blindness and severe vision loss in Australia. The future demand for eye care services and number of patients requiring treatment for AMD is expected to rise, as Australia's aging population is increasing due to longer life expectancy. Patients diagnosed with AMD typically undergo regular monthly review, which includes visual acuity assessment and optical coherence tomography (OCT). The accurate interpretation of OCT images, including the detection of macular oedema, is crucial when determining whether anti-VEGF treatment is indicated in patients with AMD.

The past decade has seen an increase in the number of orthoptist-led screening and monitoring clinics for chronic eye conditions, with orthoptists expanding their roles to include amblyopia screening, glaucoma monitoring and triage assessment. The accuracy of orthoptists in interpreting OCT images for screening and/or monitoring purposes is of particular interest given the growing demand for eye healthcare services.

This clinical audit investigated the rate of agreement between orthoptists and an ophthalmologist working in a private ophthalmology clinic in determining whether anti-VEGF treatment for AMD is indicated based on OCT appearance. Data collection for this clinical audit is still in process. The preliminary results of this audit will be discussed.

### IMAGING IN AGE-RELATED MACULAR DEGENERATION

**Kate Brassington, Chi Luu, Robyn Guymer**

Since the introduction of spectral domain OCTs there have been advances in the understanding of age-related macular degeneration (AMD) including the different stages of the disease. In the Macular Research Unit we have been following patients with the early stage of AMD with the Heidelberg Spectralis and the Cirrus OCT for two years to monitor their AMD with various imaging modalities and have been able to detect changes in the retinal layers and varying signs such as geographic atrophy before they can be seen clinically or on fundus photos. This presentation described new ways of looking at AMD through different imaging techniques and the different stages that lead to geographic atrophy in patients diagnosed with AMD.

### VISUAL OUTCOMES OF CHILDREN SEEN IN THE STEPS HIGH PRIORITY CLINIC AT THE CHILDREN'S HOSPITAL AT WESTMEAD

**Louise Brennan, Lindley Leonard**

A retrospective review of the medical records of children referred to the STEPS High Priority Clinic at The Children's Hospital at Westmead was presented. Findings discussed included initial visual acuity, contributing factors, the number of points of service, treatments initiated and final visual acuity.



## 'I CAN'T SEE ANYTHING!': IS THIS VISION LOSS FUNCTIONAL?

**Stephanie Crofts**

Investigating functional vision loss can be time-consuming and difficult in children. This presentation described how to determine functional from true visual loss in a child who 'can't see anything'.

## INVESTIGATING CATARACT REFERRAL PRACTICES UTILISED BY AUSTRALIAN OPTOMETRISTS

**Vu Quang Do, Rebecca Li, Max Ma, Christopher Pooley, Carina Trinh, Laura Peattie, Anna Palagyi, Peter McCluskey, Lisa Keay**

**Background:** The pathway to cataract surgery in Australia generally begins at the optometric level, however very little is known about the referral processes utilised. This presentation reported the findings of a survey investigating these cataract referral criteria.

**Methods:** Five-hundred-and-thirty-three of 4,272 (13%) members of the Optometrists Association of Australia responded to an emailed survey sent in April 2013. The survey included questions on demographics, professional optometric characteristics and referral criteria considerations.

**Results:** The majority of sampled optometrists (407/528, 77%) provided a visual acuity referral benchmark between 6/9 and 6/12. Hobbies (94%) and driving (73%) rated highest for earlier referral, whilst 'not wanting surgery' (79%) resulted in the largest proportion choosing to delay referral. Those practising in Australia's most advantaged socioeconomic areas were 2.4 times more likely to refer privately (95% CI 1.6-3.6), where surgical cost considerations were significant ( $p < 0.001$ ). Public waiting times were discussed by almost all optometrists (97%, median category 12-18 months) whereas a lower proportion (64%, median category 1-2 months) discussed private waiting times.

**Conclusion:** Patient-reported visual status impacted upon the overall optometric decision for cataract referral. Considerations of costs influenced choices in referral to private or public surgical services, where optometrists noted significant differences in wait-times.

## DOES TRAINING IN THE USE OF MAGNIFICATION IMPROVE OUTCOMES?

**Norliza Bt Mohamad Fadzil, Kerry Fitzmaurice**

**Introduction:** Magnification is the commonest form of vision rehabilitation. Clients are usually prescribed a device and given basic instruction in its use. This study aimed to determine if training and structured practice in the use of the device would improve outcomes.

**Method:** Twenty-four participants who did not have macular disease or nystagmus were involved in the study. All were prescribed appropriate magnifiers, given basic instruction and allowed a two-week adaptation period. Fifteen participants received ten sessions of training the remaining nine had no further intervention. Outcome measures included reading speed, print size and activities of daily living (ADL) at baseline, 7-weeks and 6-months.

**Results:** Both groups demonstrated improvement on all outcome measures which were significant ( $p \leq 0.05$ ). Maximum decrease in print size and increase in reading speed occurred between baseline and 7 weeks; further improvement in reading speed occurred at 6 months in the training group only. ADL outcomes indicated improvement in both groups; the training group at 7-weeks the non-trained group at 6 months.

The results of this study support the use of magnification devices to decrease print size, increase reading speed and to improve both self perceived and demonstrated ability to perform ADLs with training decreasing the time required.

## DO CURRENT RECOMMENDATIONS FOR THE WEARING OF SUNGLASSES BY CHILDREN COMPROMISE REFRACTIVE DEVELOPMENT?

**Amanda French, Devica Apriyani, Danielle Morgan, Timothy Roque, Nicola Saxton, Chii Xiang Yue, Kathryn Rose**

Recommendations are often made that children should wear sunglasses when outdoors from a young age to prevent exposure to ultraviolet (UV) light. UV exposure is well established to be related to the formation of cataract and pterygia and implicated in macular degeneration. However, longitudinal studies of children have not been conducted to determine the reduction in risk of developing these conditions later in life. Exposure to sunlight has recently been shown to protect children from the development of myopia, most importantly at a young age. Animal studies have shown that the mechanism behind this protective effect is high intensity light, such as sunlight, which stimulates the release of retinal dopamine and prevents excessive axial elongation. In order to have a protective effect the light must be of sufficient intensity to elicit this response and it appears that the threshold light intensity required is approximately 10,000 lux (lumen per square metre). It is unclear whether wearing sunglasses would lower the available light intensity outdoors below the threshold required for protection and whether this could affect refractive development. This study reported the reduction in luminosity levels through various commercially available sunglasses lenses in comparison to available outdoor light intensity throughout the day.

## STEPS VISION SCREENING OUTCOMES AND RESULTS: SOUTH WESTERN SYDNEY

**Kamil Gorski**

Between January and June 2013, over 5,000 children were screened through the StEPS program in the South Western Sydney Local Health District. The results and outcomes of these were discussed with particular emphasis on secondary screening of children identified as 'high priority' and 'unable' after primary StEPS screening.

## CEREBRAL VISION IMPAIRMENT: BEYOND THE OPTIC NERVE

**Kylie Gouliotis**

Cerebral vision impairment (CVI) is one of the most common eye conditions seen at the Royal Institute for Deaf and Blind Children Teleschool yet it is often misunderstood with devastating consequences for the child. Children with CVI can have visual acuity which ranges from normal to immeasurable however the child's functional vision is often severely affected. Unfortunately when only visual acuity is considered, children will often miss out on support and funding services.

Beyond the optic nerves and occipital lobe, the dorsal and ventral streams hold the key to identifying the visual behaviours of children with CVI. While damage to the optic nerves and occipital lobe can cause loss of visual acuity, contrast, colour and visual fields, damage to these higher visual processing areas impacts on visually guided movement, orientation, complexity, recognition and visual memory. This presentation discussed the visual behaviours associated with damage to the higher visual processing areas.

## RIDBC TELESCHOOL: ENABLING PARENTS AND TEACHERS TO TAKE THE LEAD

**Kylie Gouliotis**

The Royal Institute for Deaf and Blind Children Teleschool utilises video conference and web-based technologies to provide support services to children with hearing and/or vision impairment who live in regional or remote areas of Australia. When working via video conference, the consultant participates as a coach to parents and teachers, guiding them through set activities which will help the children to reach their developmental or educational goals. This approach enables parents and teachers to actively participate in their child's program leading to greater ability to integrate the skills and activities into the child's life.

This presentation discussed the techniques used to engage and enable parents and teachers. Case studies demonstrated these techniques and the results of active parent and teacher participation.

## THE EFFECT OF TESTING PROCEDURE ON PERIPHERAL VISION RESPONSES

**Neryla Jolly**

**Aim:** To raise awareness of the impact of different approaches to peripheral vision assessment.

**Method:** An initial series of cases with peripheral vision loss was presented, demonstrating the outcome of performing different test procedures. The methods of examination include: static, kinetic (stimulus presentation), assessment by central fixation compared with moving fixation during the test; awareness versus seeing the target.

**Results:** Some patients have a response that is the same regardless of the method used. Some patients show an improved response according to the method used.

## LOSING THE 'MIDDLE MAN' IN GENETIC EYE DISEASE: THE CURRENT SCOPE OF DIRECT TO CONSUMER TESTING IN OPHTHALMOLOGY

**Lisa Kearns, Maria Franchina, Seyhan Yazar, Sandra Staffieri, David Mackey, Alex Hewitt**

**Purpose:** Providing personalised genetic information may be seen as 'empowering' with individuals taking responsibility for their own health, decisions and lifestyle choices. Although there are regulations covering genetic testing, consumers can approach Direct to Consumer (DTC) companies who provide a variety of tests, ranging from paternity and ancestry screening to genetic disease risk assessment. Such services circumvent the direct pre-test consultation; thereby removing the 'middle man', the medical practitioner or genetic counsellor. This study aims to compare DTC companies and their services who offer genetic risk assessment for ophthalmic diseases.

**Methods:** Using the Google search engine, DTC company web sites were scanned using the following terms: genetic test; genetic testing; genomic test; DNA test kit; direct-to-consumer genetic tests; direct-to-consumer genomic tests; and DTC Company. Those DTCs not offering testing for at least one ophthalmological condition in humans were excluded. Information obtained included whether the service was 'truly DTC', cost to the consumer, sample source, eye diseases as well as genes or variants tested. Data were collated on results, interpretation, significance and genetic counselling services provided to the consumer and whether these were updated as additional information became available.

**Results:** Seventeen companies were identified, however two companies were not used for direct comparison after recent company takeovers. Of the companies compared 10/15 (66.66%) were 'true' DTC companies,

offering tests to a consumer without the need for a medical practitioner's input. All companies provided some level of genetic risk assessment for age-related macular degeneration. There was variation in single-nucleotide polymorphisms (SNPs) used for a given disease, with varying numbers of SNPs and loci tested.

**Significance:** Currently, there is marked variation in genetic screening provided by DTC companies for ophthalmic disease. Such variation in loci and SNPs screened, could lead many patients to receive somewhat different risk predictions if using multiple services. Some level of consumer protection could be ensured through regulation of current DTC services.

## MANAGING LONG WAIT TIMES: THE CHW REFERRAL TRIAGE PROCESS AND OUTCOMES

**Suzy King**

Prior to 2008 The Eye Clinic at The Children's Hospital at Westmead accepted all referrals into the clinic. Over the years this led to very long waiting times for appointments which became a risk to patients requiring a more urgent assessment. A referral triage process was implemented in 2008/9 and has been adjusted and adapted to suit the current demands of the clinic.

Triage is now an important daily task that plays a big part in managing clinic numbers. The triage process along with current outcomes was discussed in detail.

## HIGH PRIORITY STEPS CLINIC AT THE CHILDREN'S HOSPITAL AT WESTMEAD

**Lindley Leonard, Louise Brennan**

The Children's Hospital at Westmead runs a StEPS high priority clinic, receiving referrals of children throughout NSW who have documented visual acuity of less than 6/18 on StEPS screening. An overview of our protocol, procedures and outcomes will be discussed and a number of interesting cases highlighted.

## SMART PHONE-ASSISTED ANTERIOR SEGMENT SLIT-LAMP PHOTOGRAPHY

**Minh Anh (Andy) Ly**

Digital photography can be a useful tool for the diagnosis and monitoring of anterior segment diseases. Photography provides an objective reference of the state/progression of the disease instead of relying upon the subjectiveness of the ophthalmologist's recordings. However, the high costs involved in the purchase and maintenance of these machines can be a deterrent to clinics utilising such tools.

Alternatively, the modification of slit-lamps by mounting a smart phone can provide a more readily available method of anterior segment photography. When used in the correct manner, smart phone cameras are a capable substitute.

This presentation provided a practical and step-by-step guide to smart phone-assisted slit-lamp photography.

## DOES TEACHING APPLANATION TONOMETRY ON A SIMULATED EYE IMPROVE STUDENTS' LEARNING OF AN IMPORTANT CLINICAL SKILL?

**Stephanie Mauger, Meri Vukicevic, Stuart Keel, Nick Stonem**

**Background:** Goldmann applanation is currently the gold standard of intraocular pressure measurement and is a clinical skill used frequently by orthoptists. It is a difficult skill to teach students as the risk of corneal abrasion is high. In 2013 the use of simulation was introduced into the curriculum with a focus on assessing novice students' perception of risk, ease of learning and ability to perform the skill.

Current literature regarding the use of simulation in training programs has not been thoroughly investigated. Novice students welcome the introduction of simulation, generally reporting a direct correlation with increased confidence when performing otherwise difficult or dangerous tasks. However, teachers and supervisors report students over-compensating the worth of this self-perceived learning benefit.

The aim of this project was to assess the student perception of difficulty when learning the inherently dangerous skill of applanation tonometry and subsequent ability after being trained via simulation in comparison to being trained with the use of a human eye. Furthermore, perceptions of difficulty from a previous cohort of students (2012) were compared to current students (2013) analysing the impact of simulation on current applanation tonometry curriculum.

**Methods:** Methodology used to measure outcomes included anonymous surveys, formal and informal class assessments and focus groups.

**Results:** Early results suggest that students welcome the use of a simulated eye when first learning the skill of applanation tonometry.

## OPTIMISING REFRACTIVE OUTCOMES FOR COMBINED PHACO/VITRECTOMY

**Rachel McIntosh, Justine Wilks, Sophie Rogers, Wilson Heriot**

**Purpose:** To identify the optimal refractive outcome for combined cataract and vitrectomy patients.

**Method:** A retrospective audit was undertaken for 161 patients who underwent combined vitrectomy and cataract surgery and did not have axial length (AL) adjusted, and for 47 patients where the AL was adjusted for the potential shortening by adding OCT measured macular thickness beyond the normal ~200u.

**Results:** There was no significant difference between target spherical refractive outcome and actual spherical refractive outcome after manual AL adjustment. The target refraction and actual postop refraction however, differed significantly in the non-adjusted eyes with a mean difference of -0.17DS ( $p < 0.001$ ) and a significant difference was also seen between the two groups ( $p = 0.013$ ). The target spherical refraction using the lens selected after manual AL adjustment and the lens selected prior to AL also differed significantly ( $p = 0.0002$ ) with a median difference of +0.12 DS (IQR +0.03 to +0.42).

**Conclusion:** Combining cataract and vitrectomy surgery secures excellent visibility and prevents subsequent surgery, however the refractive outcomes can potentially be compromised by AL aberrations from abnormal reflectivity from surface membranes. This audit has demonstrated a superior refractive outcome after manual AL adjustment compared with the standard IOL power used for cataract surgery alone.

## CAN THE IMPACT OF VISION IMPAIRMENT ON A CHILD'S DAILY FUNCTIONING BE MEASURED?

**Philippa Miller, Sue Silveira**

The DisabilityCare inclusion criteria use the impact of disability on the individual's daily functioning to determine eligibility. The National Disability Insurance Scheme Act 2013 acknowledges that the individual's age and disability will determine the assessment tools used to ensure that they are relevant to the individual's situation. While visual acuity and visual field results are easier to quantify and compare, they are not the most relevant indicator of an individual's daily visual functioning. It can be assumed at this stage that functional vision assessments will play an integral part in applying for funding and support through DisabilityCare.

DisabilityCare discusses the important role that early intervention plays in reducing the support required later in life. Therefore funding will focus on improving the child's ability to perform activities of daily living. The ability to reliably determine a child's level of functional vision and apply it to inclusion criteria was questioned, particularly in the presence of additional disabilities. A literature review was carried out to explore the question: How can the impact of vision impairment on daily functioning be measured in a paediatric vision-impaired population?

## 'HELP US HELP YOU': WHAT PATIENTS CAN DO TO HELP THEMSELVES

**Julie Morrison**

There is an ever growing body of evidence about risk factors for eye disease. Although some of these, such as age, gender and genetics, cannot be changed, there are a significant number of 'modifiable' risk factors that can reduce the chances of disease occurrence and progression. People with diabetes, for example, are less likely to get sight-threatening retinopathy if they have good control of their diabetes than those with poor control.

As orthoptists, our focus is often directed at what we can do for the patient in the clinic. However, educating patients about the modifiable risk factors involved with their disease can empower them as well as improving their chances of gaining the best visual outcome. Orthoptists are well placed to deliver and reinforce these messages.

This presentation gave some straightforward tips, based on the current evidence, on what patients can do to achieve the best outcome for their eyes.

## THE RESIDENTIAL OCULAR CARE TRIAL: METHODOLOGY AND PRELIMINARY RESULTS

**Theona Nicolaou, Rachel McIntosh, Jonathan Jackson, Lauren Kharsas, Ecosse Lamoureux**

**Purpose:** To evaluate the clinical, economic and patient-centred effectiveness of a novel eye care model for visually impaired people in residential care facilities.

**Method:** A prospective, multi-centred RCT comparing Residential Ocular Care (ROC) with usual care. Those with distance vision  $< 6/12$  and/or near vision  $\leq N8$  will be invited to participate in ROC. The four interventions include the correction of refractive error, cataract surgery, low vision rehabilitation and referral to an ophthalmologist. Assessments include visual acuity testing (primary outcome); residential care vision-specific QoL; residential care-specific daily functioning; overall and vision-specific QoL; falls; depression and eye care utilisation (secondary outcomes). A cost-effectiveness analysis will be conducted. Four-hundred participants will be recruited from approximately 14 locations. A feasibility study was undertaken at Barwon Health residential care facility.

**Results:** Our feasibility study included 48 residents, 70% (33) were considered to have sufficient cognitive functioning. Of these 97% (n=31), 42 % (n=13) male, agreed to have a vision assessment. Of these, 80% (n=25) were considered to have either distance vision <6/12 and/or near vision N8 or worse. Of these 80%, 19 visual aids were provided, three participants were referred for cataract surgery, five to ophthalmic care and three to low vision rehabilitation.

**Conclusion:** Our preliminary data indicate that ROC is feasible and well accepted by residential staff and participants. We hypothesise it will improve vision, quality of life, functional abilities and depression in this population.

was diagnosed in 56 (4.3%) participants. No statistically significant association was found between strabismus and gender ( $p=0.91$ ). The exotropia:esotropia ratio was 1.24. Of the participants with strabismus, five (9.8%) had amblyopia.

**Conclusion:** The prevalence of strabismus was similar to other populations.

## ADJUSTABLE GLASSES FOR CHILDREN WITH CLIP-ON FRAMES

**Madeleine Scavone**

There is an apparent gap in the market for children's glasses that are cost-effective yet still fit the child's face well. To overcome this, a pair of glasses has been designed by the presenter that ultimately grows with the child's face to offer a tailored fit for the wearer, whilst being more economical for the parents, with the child ideally only needing one pair of glasses their whole life. The use of these adjustable glasses guarantees the wearer will always look through the lens of the glasses to promote normal visual pathway development, eliminating the risk/development of amblyopia from poorly fitting glasses. The novelty of clip-on frames entices the child to wear their glasses, with a variety of different colours and styles. These glasses will hopefully eliminate the pressure on parents to find a pair of glasses that fits the child well yet is still appealing to the child, a problem that is often solved with a compromise of one over the other. When the child grows, the glasses can easily be expanded to fit the face, and a new frame clipped on top.

## THE MORE THINGS CHANGE, THE MORE THEY STAY THE SAME: DELAYED DIAGNOSIS IN RETINOBLASTOMA

**Sandra Staffieri, Lisa Kearns, Alex Hewitt, James Elder, John McKenzie, David Mackey**

Retinoblastoma (RB) is the most common ocular cancer in children. Caused by somatic or germline mutations in the RB1 gene, it occurs sporadically or can be inherited. Leukocoria is the most common presenting sign, followed closely by strabismus and family history. Despite occasional newspaper and magazine articles, the symptoms and signs are often ignored until the disease is advanced. Both public and health worker awareness of these signs is poor, with early symptoms often ignored. Early diagnosis provides the best opportunity to maximise visual outcomes, improve globe salvage rates and save lives. Research programs to improve awareness and reduce delays in diagnosis were discussed.

## PREVALENCE OF STRABISMUS IN A YOUNG ADULT POPULATION

**Seyhan Yazar, Alex Hewitt, Jenny Mountain, David Mackey**

**Purpose:** To determine the prevalence of strabismus in a young adult population with Northern European ancestry.

**Methods:** Offspring of the Western Australian Pregnancy Cohort (Raine) Study participants have been followed from birth to young adulthood. At the age of 20 years, for the first time 1,344 participants had a comprehensive eye examination including visual acuity and a detailed orthoptic assessment. Amblyopia is defined as a difference of more than two LogMAR lines between the eyes in best-corrected visual acuity.

**Results:** Complete data was available for 1,314 participants. Strabismus



## Named Lectures, Prizes and Awards of Orthoptics Australia

### THE PATRICIA LANCE LECTURE

1988	Elaine Cornell	Home exercises in orthoptic treatment
1989	Alison Pitt	Accommodation deficits in a group of young offenders
1990	Anne Fitzgerald	Five years of tinted lenses for reading disability
1992	Carolyn Calcutt	Untreated early onset esotropia in the visual adult
1993	Judy Seaber	The next fifty years in orthoptics and ocular motility
1995	David Mackey	The Glaucoma Inheritance Study in Tasmania (GIST)
1997	Robin Wilkinson	Heredity and strabismus
1998	Pierre Elmurr	The visual system and sports performance
1999	Kerry Fitzmaurice	Research: A journey of innovation or rediscovery?
2005	Kathryn Rose	The Sydney Myopia Study: Implications for evidence based practice and public health
2006	Frank Martin	Reading difficulties in children - evidence base in relation to aetiology and management
2008	Stephen Vale	A vision for orthoptics: An outsider's perspective
2009	Michael Coote	An eye on the future
2010	John Crompton	The pupil: More than the aperture of the iris diaphragm
2011	Neryla Jolly	On being an orthoptist
2012	Shayne Brown	A snapshot of orthoptics from the 1960s to 2000
2013	Sue Silveira	Finding the leader within

### THE EMMIE RUSSELL PRIZE

1957	Margaret Kirkland	Aspects of vertical deviation
1959	Marion Carroll	Monocular stimulation in the treatment of amblyopia exanopsia
1960	Ann Macfarlane	A study of patients at the Children's Hospital
1961	Ann Macfarlane	A case history "V" Syndrome
1962	Adrienne Rona	A survey of patients at the Far West Children's Health Scheme, Manly
1963	Madeleine McNess	Case history: Right convergent strabismus
1965	Margaret Doyle	Diagnostic pleoptic methods and problems encountered
1966	Gwen Wood	Miotics in practice
1967	Sandra Hudson Shaw	Orthoptics in Genoa
1968	Leslie Stock	Divergent squints with abnormal retinal correspondence
1969	Sandra Kelly	The prognosis in the treatment of eccentric fixation
1970	Barbara Denison	A summary of pleoptic treatment and results
1971	Elaine Cornell	Paradoxical innervation
1972	Neryla Jolly	Reading difficulties
1973	Shayne Brown	Uses of fresnel prisms
1974	Francis Merrick	The use of concave lenses in the management of intermittent divergent squint
1975	Vicki Elliott	Orthoptics and cerebral palsy
1976	Shayne Brown	The challenge of the present
1977	Melinda Binovec	Orthoptic management of the cerebral palsied child
1978	Anne Pettigrew	
1979	Susan Cort	Nystagmus blocking syndrome
1980	Sandra Tait	Foveal abnormalities in ametropic amblyopia
1981	Anne Fitzgerald	Assessment of visual field anomalies using the visually evoked response
1982	Anne Fitzgerald	Evidence of abnormal optic nerve fibre projection in patients with dissociated vertical deviation: A preliminary report
1983	Cathie Searle	Acquired Brown's syndrome: A case report
	Susan Horne	Acquired Brown's syndrome: A case report
1984	Helen Goodacre	Minus overcorrection: Conservative treatment of intermittent exotropia in the young child
1985	Cathie Searle	The newborn follow up clinic: A preliminary report of ocular anomalies
1988	Katrina Bourne	Current concepts in restrictive eye movements: Duane's retraction syndrome and Brown's syndrome
1989	Lee Adams	An update in genetics for the orthoptist: A brief review of gene mapping
1990	Michelle Gallaher	Dynamic visual acuity versus static visual acuity: Compensatory effect of the VOR
1991	Robert Sparkes	Retinal photographic grading: The orthoptic picture

1994	Rebecca Duyshart	Visual acuity: Area of retinal stimulation
1995-7	Not awarded	
1998	Nathan Clunas	Quantitative analysis of the inner nuclear layer in the retina of the common marmoset callithrix jacchus
1999	Anthony Sullivan	The effects of age on saccades made to visual, auditory and tactile stimuli
2001	Monica Wright	The complicated diagnosis of cortical vision impairment in children with multiple disabilities
2005	Lisa Jones	Eye movement control during the visual scanning of objects
2006	Josie Leone	The prognostic value of the cyclo-swap test in the treatment of amblyopia using atropine
2007	Thong Le	What is the difference between the different types of divergence excess intermittent exotropia?
2008	Amanda French	Does the wearing of glasses affect the pattern of activities of children with hyperopic refractive errors?
2009	Amanda French	Wide variation in the prevalence of myopia in schools across Sydney: The Sydney Myopia Study
2010	Alannah Price	Vertical interline spacing and word recognition using the peripheral retina
2011	Amanda French	Comparison of the distribution of refraction and ocular biometry in European Caucasian children living in Northern Ireland and Sydney
2012	Melanie Cortes	Treatment outcomes of children with vision impairment detected through the StEPS program
2013	Jess Boyle	The accuracy of orthoptists in interpreting macular OCT images

### PAEDIATRIC ORTHOPTIC AWARD

---

1999	Valerie Tosswill	Vision impairment in children
2000	Melinda Syminiuk	Microtropia - a challenge to conventional treatment strategies
2001	Monica Wright	The complicated diagnosis of cortical vision impairment in children with multiple disabilities
2005	Kate Brassington	Amblyopia and reading difficulties
2006	Lindley Leonard	Intermittent exotropia in children and the role of non-surgical therapies
2007	Jody Leone	Prevalence of heterophoria in Australian school children
2008	Jody Leone	Can visual acuity screen for clinically significant refractive errors in teenagers?
2009	Jody Leone	Visual acuity testability with the electronic visual acuity-tester compared with LogMAR in Australian pre-school children
2010	Fiona Gorski	Neurofibromatosis and associated ocular manifestations
2011	Suzy King	Understanding Sturge-Weber syndrome and the related ocular complications
2012	Jane Scheetz	Accuracy of orthoptists in the diagnosis and management of triaged paediatric patients
2013	Louise Brennan	Visual outcomes of children seen in the StEPS High Priority Clinic at The Children's Hospital at Westmead

### THE MARY WESSON AWARD

---

1983	Diana Craig (Inaugural)
1986	Neryla Jolly
1989	Not awarded
1991	Kerry Fitzmaurice
1994	Margaret Doyle
1997	Not Awarded
2000	Heather Pettigrew
2004	Ann Macfarlane
2008	Julie Barbour
2010	Elaine Cornell
2011	Zoran Georgievski

### ZORAN GEORGIEVSKI MEDAL

---

2012	Neryla Jolly (Inaugural)
2013	Connie Koklanis

## Presidents of Orthoptics Australia and Editors of The Australian Orthoptic Journal

### PRESIDENTS OF ORTHOPTICS AUSTRALIA

1945-7	Emmie Russell	1964-5	Lucy Retalic	1981-82	Marion Rivers
1947-8	Lucy Willoughby	1965-6	Beverly Balfour	1982-3	Jill Stewart
1948-9	Diana Mann	1966-7	Helen Hawkeswood	1983-5	Neryla Jolly
1949-50	E D'Ombrian	1967-8	Patricia Dunlop	1985-6	Geraldine McConaghy
1950-1	Emmie Russell	1968-9	Diana Craig	1986-7	Alison Terrell
1951-2	R Gluckman	1969-70	Jess Kirby	1987-9	Margaret Doyle
1952-4	Patricia Lance	1970-1	Neryla Heard	1989-91	Leonie Collins
1954-5	Diana Mann	1971-2	Jill Taylor	1991-3	Anne Fitzgerald
1955-6	Jess Kirby	1972-3	Patricia Lance	1993-5	Barbara Walsh
1956-7	Mary Carter	1973-4	Jill Taylor	1995-7	Jan Wulff
1957-8	Lucille Retalic	1974-5	Patricia Lance	1997-00	Kerry Fitzmaurice
1958-9	Mary Peoples	1975-6	Megan Lewis	2000-2	Kerry Martin
1959-60	Patricia Lance	1976-7	Vivienne Gordon	2002-4	Val Tosswill
1960-1	Helen Hawkeswood	1977-8	Helen Hawkeswood	2004-6	Julie Barbour
1961-2	Jess Kirby	1978-9	Patricia Dunlop	2006-8	Heather Pettigrew
1962-3	Patricia Lance	1979-80	Mary Carter	2008-10	Zoran Georgievski
1963-4	Leonie Collins	1980-1	Keren Edwards	2010-13	Connie Koklanis

### EDITORS OF THE AUSTRALIAN ORTHOPTIC JOURNAL

Vol 8 1966	Barbara Lewin & Ann Metcalfe	Vol 22 1985	Margaret Doyle	Vol 37 2003	Neryla Jolly & Kathryn Thompson
Vol 9 1969	Barbara Dennison & Neryla Heard	Vol 23 1986	Elaine Cornell	Vol 38 2004-05	Neryla Jolly & Kathryn Thompson
Vol 10 1970	Neryla Heard	Vol 24 1987	Elaine Cornell	Vol 39 2007	Zoran Georgievski & Connie Koklanis
Vol 11 1971	Neryla Heard & Helen Hawkeswood	Vol 25 1989	Elaine Cornell	Vol 40 2008	Connie Koklanis & Zoran Georgievski
Vol 12 1972	Helen Hawkeswood	Vol 26 1990	Elanie Cornell	Vol 41 2009	Zoran Georgievski & Connie Koklanis
Vol 13 1973-74	Diana Craig	Vol 27 1991	Julia Kelly	Vol 42 2010	Connie Koklanis & Zoran Georgievski
Vol 14 1975	Diana Craig	Vol 28 1992	Julia Kelly	Vol 43 2011	Connie Koklanis
Vol 15 1977	Diana Craig	Vol 29 1993	Julia Kelly	Vol 44 2012	Connie Koklanis & Linda Santamaria
Vol 16 1978	Diana Craig	Vol 30 1994	Alison Pitt	Vol 45 2013	Connie Koklanis & Linda Santamaria
Vol 17 1979-80	Diana Craig	Vol 31 1995	Julie Green		
Vol 18 1980-81	Diana Craig	Vol 32 1996	Julie Green		
Vol 19 1982	Diana Craig	Vol 33 1997-98	Julie Green		
Vol 20 1983	Margaret Doyle	Vol 34 1999	Julie Green		
Vol 21 1984	Margaret Doyle	Vol 35 2000	Neryla Jolly & Nathan Moss		
		Vol 36 2001-02	Neryla Jolly & Kathryn Thompson		

## Orthoptics Australia Office Bearers, State Branches & University Training Programs

### ORTHOPTICS AUSTRALIA

---

#### ORTHOPTICS AUSTRALIA OFFICE BEARERS

---

**President:** Meri Vukicevic  
**Vice President:** Connie Koklanis  
**President Elect:** Meri Vukicevic  
**Treasurer:** Karen Mill  
**Secretary:** Stuart Keel  
**Public Officer:** Jody Leone

#### STATE REPRESENTATIVES

---

**Australian Capital Territory:** Andy Ly  
**New South Wales:** Michelle Courtney-Harris, Eyal Pat, Neryla Jolly  
**Queensland:** Paul Cawood, Keren Edwards, Julie Hall  
**South Australia:** Shandell Moore  
**Tasmania:** Julie Barbour  
**Victoria:** Karen Mill, Catherine Mancuso, Stuart Keel  
**Western Australia:** Kate Hanman

#### STATE BRANCHES

---

**New South Wales:**  
 President: Michelle Courtney-Harris  
 Secretary: Amanda French  
 Treasurer: Lindley Leonard

**Queensland:**  
 Contact: Paul Cawood

**South Australia:**  
 Contact: Shandell Moore

**Tasmania:**  
 Contact: Julie Barbour

**Victoria:**  
 President: Catherine Mancuso  
 Secretary: Jessica Boyle  
 Treasurer: Donna Corcoran

**Western Australia:**  
 Contact: Kate Hanman

### UNIVERSITY TRAINING PROGRAMS

---

#### MELBOURNE

---

Department of Clinical Vision Sciences  
 Faculty of Health Sciences  
 La Trobe University  
 Bundoora, VIC 3086  
 T: 03 9479 5285  
 F: 03 9479 3692  
[www.latrobe.edu.au/courses/orthoptics](http://www.latrobe.edu.au/courses/orthoptics)

#### SYDNEY

---

Discipline of Orthoptics  
 Faculty of Health Sciences  
 The University of Sydney  
 East St, Lidcombe, NSW 2141  
 T: 02 9351 9250  
 F: 02 9351 9359  
[www.fhs.usyd.edu.au/orthoptics](http://www.fhs.usyd.edu.au/orthoptics)