

## Two Cases of Valsalva Retinopathy Treated with Nd:YAG Laser Hyaloidotomy

Suzane Vassallo, PhD AOBR<sup>1,2</sup>  
Catherine Mancuso, BOrth AOBR<sup>2</sup>  
C. Alex Harper, FRANZCO<sup>2,3</sup>

<sup>1</sup>Department of Clinical Vision Sciences, La Trobe University, Melbourne, Australia

<sup>2</sup>Victoria Parade Eye Consultants, St. Vincent's Medical Centre, Melbourne, Australia

<sup>3</sup>Centre for Eye Research Australia, Melbourne, Australia

### ABSTRACT

Activities involving straining can result in a haemorrhagic retinopathy which may cause sudden loss of vision. This is known as Valsalva retinopathy. Though the fundus findings can vary, a premacular haemorrhage is often seen which may resolve spontaneously over several months. Acute management of such cases can be achieved via neodymium

(Nd):YAG laser hyaloidotomy. Even in the presence of a large haemorrhage the prognosis is excellent in an otherwise healthy eye. Two cases of Valsalva retinopathy are presented.

**Keywords:** Valsalva maculopathy, Nd:YAG laser hyaloidotomy, retinal haemorrhage

### INTRODUCTION

Valsalva hemorrhagic retinopathy was first described by Duane<sup>1</sup> in 1972. As the description suggests, the retinopathy arises following a Valsalva manoeuvre wherein forcible exhalation occurs against a closed glottis. The manoeuvre causes an increase in intrathoracic and/or intra-abdominal pressure, with an accompanying increase in venous pressure in the upper parts of the body, including the eye<sup>1</sup>. A sudden elevation in intraocular venous pressure may cause normal or abnormal perifoveal capillaries to haemorrhage – immediate and painless loss of vision ensues in an otherwise healthy eye<sup>2</sup>. Vision loss is commonly unilateral<sup>3</sup>.

Valsalva retinopathy has been reported to occur during labour<sup>4</sup>, heavy lifting (including weight lifting)<sup>3, 5, 6</sup>, fiberoptic gastroenteroscopy<sup>7</sup>, rigorous sexual activity<sup>8</sup>, blowing balloons<sup>9</sup> and colonoscopy<sup>10</sup>. Coughing, sneezing or vomiting are also commonly cited aetiologies<sup>1, 2</sup>.

The fundus findings observed with this type of retinopathy varies. The picture may range from one of isolated localised oedema<sup>1</sup>, or a small well circumscribed parafoveal preretinal haemorrhage<sup>3</sup>, to a massive dome-shaped haemorrhage of

up to 5 disc diameters<sup>11</sup> or more<sup>8</sup> in size. The latter may serve to completely obscure the fovea. The size of the haemorrhage seems to correlate with the amount of venous pressure endured during the manoeuvre<sup>1</sup>.

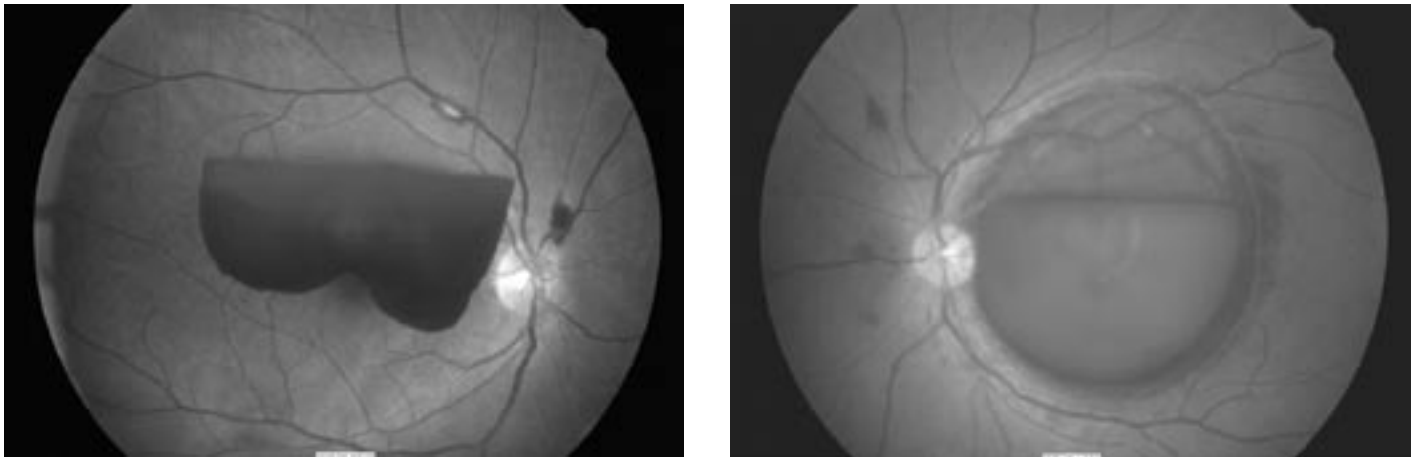
The haemorrhage in Valsalva retinopathy may be located between the internal limiting membrane (ILM) and retinal nerve fibre layer (sub-ILM)<sup>12</sup>, or between the posterior hyaloid face and the ILM (subhyaloid)<sup>2</sup>. It could also be in both locations<sup>2</sup>. The position of the haemorrhage is clinically difficult to differentiate via slit-lamp biomicroscopy<sup>13</sup>, though fine striae and a glistening light reflex on the haemorrhage surface favours a sub-ILM lesion<sup>2, 6, 12</sup>. A more definitive diagnosis appears possible using optical coherence tomography (OCT). Recent findings from two patients<sup>6</sup> highlight that the location of the haemorrhage in Valsalva retinopathy is most likely sub-ILM. While this view has been supported by others<sup>12</sup>, the posterior hyaloid face and ILM are not always visible on OCT in the presence of a premacular haemorrhage<sup>7</sup>.

Valsalva retinopathy can lead to sudden temporary loss of binocular function. The haemorrhage is usually self-limiting, clearing spontaneously over weeks to months<sup>3, 7</sup>. Intervention in the form of neodymium (Nd):YAG laser<sup>14</sup> or vitrectomy<sup>6</sup> can assist in more rapid visual recovery. While the fundus view can appear striking, a very good prognosis is likely. Two cases of Valsalva retinopathy are presented.

Correspondence: **Dr Suzane Vassallo**

Department of Clinical Vision Sciences, La Trobe University, VIC 3086, Australia.

Email: S.Vassallo@latrobe.edu.au



**Figure 1.** A. Case 1: Right eye fundus at initial presentation B. Case 2: Left eye fundus at initial presentation

**CASE 1**

A 46-year-old female presented 3-days following sudden loss of vision in her right eye. Upon specific questioning she reported occasional coughing during the 2 weeks prior to her visit, though denied heavy lifting and vomiting. Past ocular history was unremarkable. Her general health, including blood pressure, was normal (105/80 mmHg) and she was not taking any form of medication. Family history was not significant.

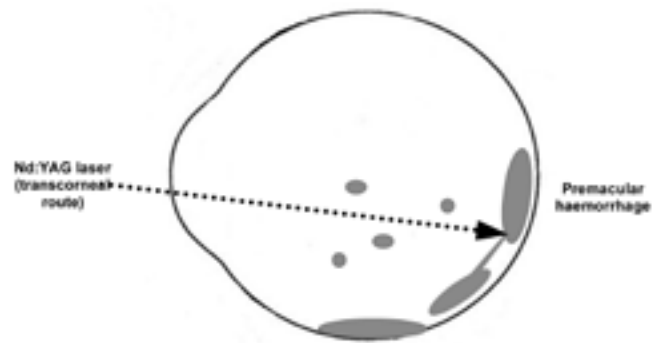
Unaided visual acuities were Right (R.) 6/24 Left (L.) 6/18, though each eye improved with pinhole to 6/9, 6/6, respectively. Refraction was not performed at this visit. Intraocular pressure was R. 8 mmHg and L. 9 mmHg. Pupils were equally reactive to light and were dilated with g. tropicamide 1% and g. phenylephrine 10%. Right eye fundus examination revealed a large premacular haemorrhage with foveolar sparing (Figure 1A). The area of the haemorrhage was approximately 5.5 disc diameters and was thought to be subhyaloid. The foveola sparing permitted relatively good visual acuity in this eye (with pinhole), despite the size of the lesion and the patient’s presenting complaint. The left eye fundus was normal.

**CASE 2**

A 28-year-old male Indian student presented with a 4-day history of a red spot obscuring the central visual field in his left eye. Aside from occasional sneezing, he denied any other Valsalva activity. His general health and family history were unremarkable and he was not taking prescription or non-prescription medication. He was a moderate myope (R. and L. -4.00 DS) and prone to developing chalazia.

Corrected visual acuities were R. 6/4 and L. count fingers

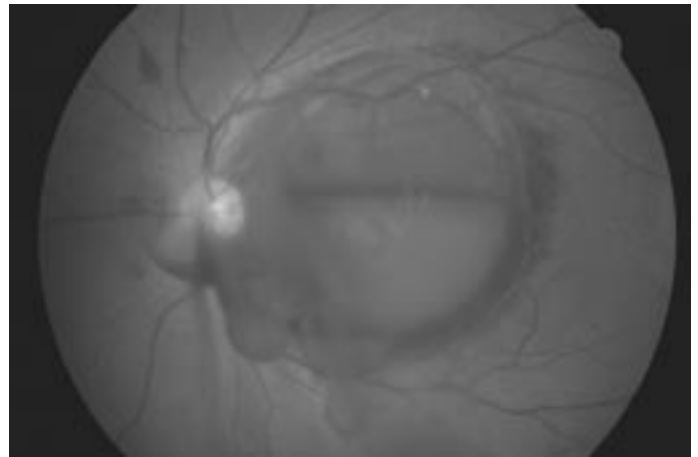
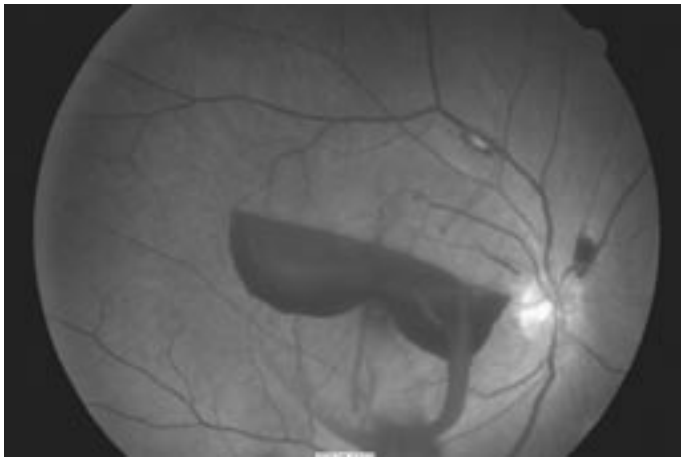
(CF) when viewing eccentrically with this eye. Intraocular pressures were R. 13 mmHg and L. 14 mmHg. Pupils were equally reactive to light and were dilated with g. tropicamide 1% and g. phenylephrine 10%. In the left eye, fundus examination revealed a large subhyaloid haemorrhage of about 5 disc diameters in area (Figure 1B). Retinal nerve fibre layer haemorrhages were also evident. The right eye fundus was unremarkable.



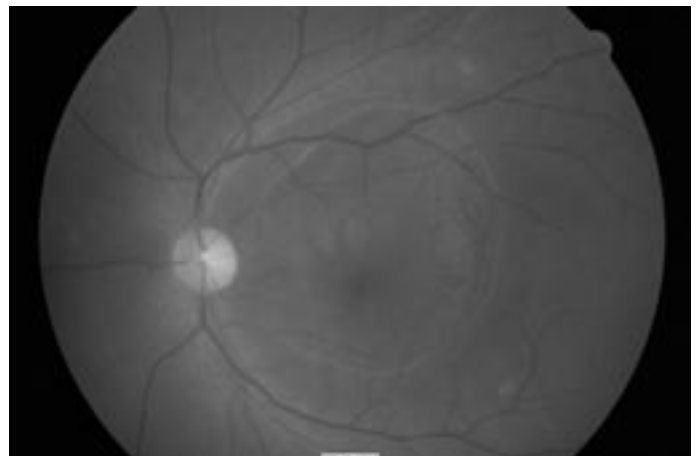
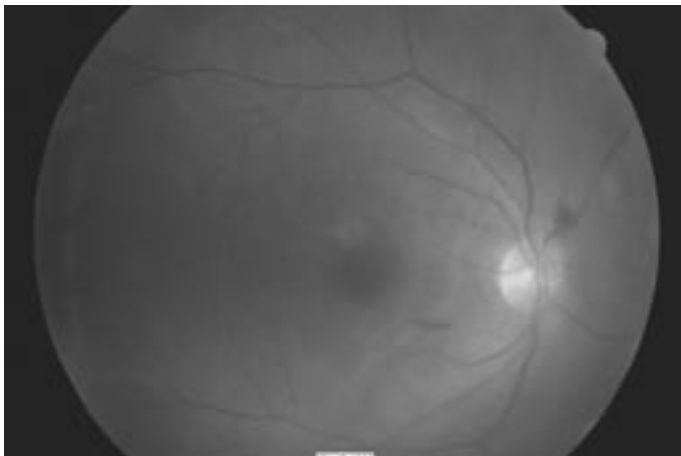
**Figure 2.** Schematic representation of Nd:YAG laser hyaloidotomy (lateral view). With gravity, blood pools inferiorly in the vitreous where it breaks down over time and is resorbed.

**MANAGEMENT**

Both cases were managed in the clinic on the day of their presentation with a single shot of Nd:YAG laser (Coherent, Santa Clara, CA) (pulse power 3.2 mJ) to the anterior surface of the posterior hyaloid membrane in an attempt to drain the haemorrhage. The procedure is referred to as a hyaloidotomy or membranotomy. The laser was aimed at the inferior portion of the haematoma, away from the fovea



**Figure 3.** Case 1(left) and Case 2 (right) approximately 15 minutes post Nd:YAG hyaloidotomy. The haemorrhage begins to clear rapidly in both cases.



**Figure 4.** Case 1: One week post Nd:YAG hyaloidotomy. Note the vitreous haze from the haemorrhage dispersion. (Fundus photograph unavailable for Case 2)

**Figure 5.** Case 2: Seven weeks post Nd:YAG hyaloidotomy. The retinal state has returned to normal. (Fundus photograph unavailable for Case 1).

(Figure 2). In each case, the haemorrhage began to drain immediately post treatment (Figure 3).

Both cases were reviewed one week post laser treatment and both reported an improvement in visual acuity. The fundal view showed vitreous haze, consistent with dispersion of the haemorrhage into the vitreous gel (Figure 4). When compared with the first visit, Case 1 demonstrated clinically stable visual acuities with R. 6/24 L. 6/18, and improvement to 6/5 bilaterally was obtained with refractive correction (R. -3.00/+0.75 x 10° L. -1.50DS). She was monitored for about 3 months post treatment, during which time her right eye vision remained stable. She was then discharged.

Case 2's corrected left eye visual acuity had improved to 6/18- one week post treatment (having initially presented with CF eccentrically). He noted black dots in his left visual field. This continued to clear over subsequent visits. Seven weeks post hyaloidotomy his corrected left eye visual acuity returned to 6/4 and the haemorrhage had completely cleared (Figure 5). Further review was not required.

## DISCUSSION

These findings confirm that Nd:YAG laser to the posterior hyaloid face is a safe, rapid and effective intervention in the treatment of premacular haemorrhage arising from Valsalva retinopathy<sup>4, 11, 13-17</sup>. Vision is restored as the blood clears away from the visual axis. The same treatment modality can be used when managing premacular haemorrhages arising from diabetic retinopathy, vein occlusion or retinal macroaneurysm<sup>11</sup>. Although the two cases presented here were not followed beyond 2 to 3 months, those followed for up to 2 years or more have not displayed retinal or choroidal injury from Nd:YAG laser treatment for premacular haemorrhage<sup>13, 18</sup>.

Nd:YAG laser photodisruption was first described in the German literature in 1988<sup>17</sup> when multiple laser shots were used to drain the haemorrhage. Since then, the technique has been somewhat modified so that a single laser shot is often used, with 2 to 3 subsequent shots<sup>4, 13, 14</sup> employed

when little drainage is evident from the first<sup>13, 14</sup>. Favardin et al.<sup>15</sup> have used up to 10 shots to clear a premacular haemorrhage arising from diabetic retinopathy.

Nd:YAG hyaloidotomy is considered most effective in treating a premacular haemorrhage of greater than 3 disc diameters in area and of no more than 3 weeks' duration<sup>18</sup>. Treating a large lesion assists in ensuring the laser beam is located away from the fovea – the laser site should be at the inferior margin of the haemorrhage<sup>11, 13, 14</sup>. This reduces the risk of a foveal injury and promotes maximal drainage through the assistance of gravity<sup>16</sup>. The presence of underlying blood is also necessary at the laser site to ensure the retina is protected at this location<sup>11</sup>. A long-standing haemorrhage can be difficult to drain due to blood clotting<sup>15</sup>, although a recent report confirms drainage of longstanding altered blood<sup>19</sup>. Others<sup>20</sup> advocate laser treatment for haemorrhages of less than 2 weeks' duration. Once the blood has drained into the vitreous, it breaks down over time and is spontaneously resorbed. It has been suggested that patients be informed to sleep in an upright position to encourage blood settling inferiorly<sup>21</sup>.

Conservative management of Valsalva retinopathy involves observation. Generally, the premacular haemorrhage can completely resolve over several months, with full visual recovery in a healthy eye<sup>1-3, 7</sup>. However, such an approach should be reserved for small haemorrhages for these are not suitable for Nd:YAG laser intervention due to the potential for foveal damage<sup>18</sup>. Prompt intervention may be offered for large haemorrhages to speed resolution and restore vision.

Vitreotomy is an option to drain the premacular haemorrhage caused by Valsalva retinopathy<sup>6</sup>, however, Nd:YAG laser membranotomy is quick, far less invasive and has fewer potential side effects. The use of vitrectomy in treating premacular haemorrhage due to diabetic eye disease is well established<sup>22</sup>.

It has been suggested that patients be informed to exhale during straining or lifting heavy objects so as to prevent a closed glottis and possible retinal damage<sup>5</sup>. It would also be apt to advise patients about the possibility of haemorrhage recurrence where this is considered likely<sup>5</sup>. Finally, reassuring the patient about their prognosis cannot be underestimated<sup>3</sup> and should constitute part of the management approach as well. Many<sup>4, 13, 14</sup> have suggested randomised prospective trials are required to differentiate the mode of treatment which is best for a premacular haemorrhage.

Even though both cases reported were somewhat myopic, there appears no predilection for Valsalva retinopathy with respect to refractive error, age, race or sex<sup>21</sup>. Another aetiology which should be considered when assessing cases of Valsalva retinopathy is the competency of the valve in each internal jugular vein. This is the only valve between the heart and the brain and serves to prevent retrograde venous flow. Diagnosis of a faulty valve is possible via

ultrasound investigation<sup>23</sup>. In such cases, patients may not present with a history of a Valsalva manoeuvre per se. These patients would need to be informed about the likelihood of haemorrhage recurrence.

The location of the premacular haemorrhage was thought to be subhyaloid in both cases presented. Striae were not evident on the haemorrhage surface as would be the case for a sub-ILM haemorrhage<sup>2, 6</sup>. Also, it has been postulated that when Nd:YAG laser membranotomy is performed on a sub-ILM haemorrhage, epimacular membrane formation is more likely to result<sup>6</sup>. This was not noted in the cases presented here but perhaps a longer follow-up is required<sup>24</sup>. The rapidity with which the haemorrhage drained is suggestive of a subhyaloid bleed as well<sup>14</sup>. While OCT imaging was not performed in the investigation of these cases, the management options for Valsalva retinopathy would not differ depending upon haemorrhage location<sup>14</sup>.

## CONCLUSION


Complete resolution of the haemorrhage in Valsalva retinopathy results in an excellent outcome. The findings from the cases presented here support the use of Nd:YAG hyaloidotomy in its management. It appears a safe and effective means of promoting the rapid return of visual acuity to its former state in an otherwise healthy eye. Patients can be reassured about their visual prognosis.

## REFERENCES

1. Duane TD. Valsalva hemorrhagic retinopathy. *Trans Am Ophthalmol Soc* 1972;70:298-313.
2. Gass JDM. Stereoscopic atlas of macular diseases: diagnosis and treatment. 3rd ed. Vol. 2. St. Louis: C.V. Mosby, 1987:564.
3. Chapman-Davies A, Lazarevic A. Valsalva maculopathy. *Clin Exp Optom* 2002;85:42-45.
4. Ladjimi A, et al. Valsalva retinopathy induced by labour. *Eur J Ophthalmol* 2002;12:336-338.
5. Romano PE. Exhale while lifting or straining to avoid Valsalva retinopathy or bleeding from stressed retinal vessels. *Eur J Ophthalmol* 2003;13:113.
6. Shukla D, Naresh KB, Kim R. Optical coherence tomography findings in Valsalva retinopathy. *Am J Ophthalmol* 2005;140:134-136.
7. Choi S, Lee S, Rah S. Valsalva retinopathy associated with fiberoptic gastroenteroscopy. *Can J Ophthalmol* 2006;41:491-493.
8. Friberg TR, Braunstein RA, Bressler NM. Sudden visual loss associated with sexual activity. *Arch Ophthalmol* 1995;113:738-742.
9. Georgiou T, Pearce I, Taylor R. Valsalva retinopathy associated with blowing balloons. *Eye* 1999;13:686-687.
10. Oboh AM, Weilke F, Sheindlin J. Valsalva retinopathy as a complication of colonoscopy. *J Clin Gastroenterol* 2004;38:793-794.
11. Rennie CA, et al. Nd:YAG laser treatment for premacular subhyaloid haemorrhage. *Eye* 2001;15:519-524.
12. Meyer CH, et al. Is the location of Valsalva hemorrhages submembranous or subhyaloid? *Am J Ophthalmol* 2006;141:231.
13. Çelebi S, Kükner AS. Photodisruptive Nd:YAG laser in the management of

- premacular subhyaloid hemorrhage. *Eur J Ophthalmol* 2000;11:281-286.
14. Raymond L. Neodymium:YAG laser treatment for hemorrhages under the internal limiting membrane and posterior hyaloid face in the macula. *Ophthalmology* 1995;102:406-411.
  15. Farvardin M, et al. Neodymium:YAG laser treatment for premacular hemorrhage. *Arch Iranian Med* 2005;8:8-13.
  16. Durukan H, et al. Photodisruptive neodymium:yttrium-aluminum-garnet laser in the management of premacular subhyaloid haemorrhage. *Asian J Ophthalmol* 2002;4:10-12.
  17. Faulborn J. Behandlung einer diabetischen pramakularen Blutung mit dem Q-switched Neodym:YAG laser. *Spektrum Augenheilkd* 1988;2:33-35. cited in: Raymond L. Neodymium:YAG laser treatment for hemorrhages under the internal limiting membrane and posterior hyaloid face in the macula. *Ophthalmology* 1995;102:406-411.
  18. Durukan AH, et al. Long-term results of Nd:YAG laser treatment for premacular subhyaloid haemorrhage owing to Valsalva retinopathy. *Eye* 2006;September 1:doi:10.1038/sj.eye.6702574.
  19. Aralikatti AKV, Haridas AS, Smith MA. Delayed Nd:YAG laser membranotomy for traumatic premacular hemorrhage. *Arch Ophthalmol* 2006;124:1503.
  20. Chen Y, Kou H. Krypton laser membranotomy for premacular hemorrhage. *Ophthalmologica* 2004;218:368-371.
  21. Duszak RS. Retinopathy, Valsalva. 2006 Oct [cited 2 Nov 2006]; Available from: URL: <http://www.emedicine.com/OPH/topic769.htm>
  22. O'Hanley GP, Canny CL. Diabetic dense premacular hemorrhage: a possible indication for prompt vitrectomy. *Ophthalmology* 1985;92:507-511.
  23. Nedelmann M, Eicke BM, Dieterich M. Functional and morphological criteria of internal jugular valve insufficiency as assessed by ultrasound. *J Neuroimaging* 2005;15:70-75.
  24. Kwok AK, Lai TY, Chan NR. Epiretinal membrane formation with internal limiting membrane wrinkling after Nd:YAG laser membranotomy in Valsalva retinopathy. *Am J Ophthalmol* 2003;136:763-766.

## The 64th Annual Scientific Conference of the Orthoptic Association of Australia



The Orthoptic Association of Australia is pleased to announce the Annual Scientific Conference will be held from **25-28 November** in **Perth** at the Burswood Entertainment Complex. Perth will offer a unique back-drop for the conference and the social program will allow delegates to experience the best of the city's entertainment, attractions and food. The

scientific committee is preparing a diverse program which aims to disseminate and share knowledge, exchange ideas and promote collaboration.

The scientific committee invites submissions of abstracts for oral (~12-15 min), rapid fire (5-10 min) or poster presentations. Abstracts must be emailed as a Word document attachment and include the following: name & address of corresponding author, presenter/s name and affiliation/s, abstract type (oral, rapid fire or poster), abstract title, abstract, short biography of presenter, eligibility for the Emmie Russell Prize and/or the Paediatric Orthoptic Prize, and expression of interest to submit a manuscript for rapid publication in the *Australian Orthoptic Journal*. The abstract should not exceed 250 words and the biography no more than 50 words. All abstracts must be emailed to Connie Koklanis [k.koklanis@latrobe.edu.au](mailto:k.koklanis@latrobe.edu.au) no later than Tuesday 11th September 2007.

Further details of the conference will soon be published on the OAA website [www.orthoptics.org.au](http://www.orthoptics.org.au) We look forward to you joining us for what will undoubtedly be a stimulating and memorable meeting. **Francine Hyde**, Conference Convenor **Connie Koklanis**, Scientific Program Coordinator **Zoran Georgievski**, Scientific Program Coordinator