

## Temperature - A Contributing Factor in a Case of Superior Oblique Palsy

Kirsty Somerville McAlester, BMedSci(Orthoptics)Hons  
Julia Kelly, DOBA MHSM

Orthoptic Department, Sydney Hospital & Sydney Eye Hospital, Sydney, Australia

### ABSTRACT

An unusual case of superior oblique palsy with vertical diplopia, exacerbated by temperature change is presented. The presenting symptoms raised suspicion of a clinical condition akin to that of "Uhthoff's Phenomenon" as seen in multiple sclerosis, however, the increased temperature in this patient led to diplopia not vision impairment. The clinical signs are presented, together with the investigations

which were undertaken in order to determine whether the suspected diagnosis of Ocular Myasthenia Gravis (OMG) could be confirmed. The clinical findings are examined in light of current evidence regarding diagnostic tests for OMG. Special attention is given to the 'Ice Test', a simple clinical test that aids in the diagnosis of OMG.

**Keywords:** Ice Test, Ocular Myasthenia Gravis, superior oblique palsy, temperature.

### INTRODUCTION

Superior oblique palsy is recognised as a common ocular motility defect seen in clinical practice.<sup>1,2</sup> A large majority of superior oblique palsies are congenital, however, acquired superior oblique palsies are also frequently encountered.<sup>2</sup> Numerous aetiologies for acquired superior oblique palsies are cited in the literature for example trauma, inflammation, vascular, infection and tumour.<sup>1-3</sup> Ocular myasthenia gravis (OMG), which can mimic any form of pupil sparing, non-restrictive ocular motility defect, is also reported as a possible, yet rare aetiology of superior oblique palsy.<sup>4</sup> However, it is often not possible to identify the aetiology of a superior oblique palsy, with some authors reporting 23% - 38% of cases being idiopathic.<sup>3,5</sup>

This paper presents an unusual case of superior oblique palsy with vertical diplopia, which was exacerbated by increased ambient temperature. The presenting symptom raised suspicion of a clinical reaction that appeared to be akin to that of "Uhthoff's Phenomenon" seen in multiple sclerosis<sup>6</sup>, however the increased temperature led to diplopia, not vision impairment. An extensive literature search did not provide

evidence of similar cases of superior oblique palsy where increased temperature contributed to decompensation and/or an increase in symptoms. However, several studies have documented increases and decreases in temperature that affect motor and sensory nerve conduction velocity in muscles and have profound effects in neuromuscular conditions such as myasthenia gravis (MG).<sup>7-9</sup>

### CASE REPORT

A healthy 53-year-old male presented in mid-summer, complaining of a three-year history of reoccurring, intermittent, vertical diplopia. Three years previously there was sudden onset of diplopia accompanied by loss of depth perception, balance impairment and neck pain. The patient underwent extensive neurological and ophthalmological investigations including MRI, CT scans and a Tensilon test. To the patient's knowledge all results were within normal limits. He was however prescribed a prismatic correction which alleviated the diplopia.

The main complaint on presentation to the orthoptic department was that during periods of hot weather and high temperature an increase in vertical diplopia was experienced, which was no longer controlled by the prismatic correction incorporated in the glasses unless a compensatory head posture (CHP) was used. Interestingly, the patient reported that the prismatic correction was not

Correspondence: **Kirsty Somerville McAlester**  
Orthoptic Department, Sydney Hospital & Sydney Eye Hospital,  
8 Macquarie Street, Sydney, NSW 2000, Australia.  
Email: [KirstySomerville.Mcalester@sesiahs.health.nsw.gov.au](mailto:KirstySomerville.Mcalester@sesiahs.health.nsw.gov.au)

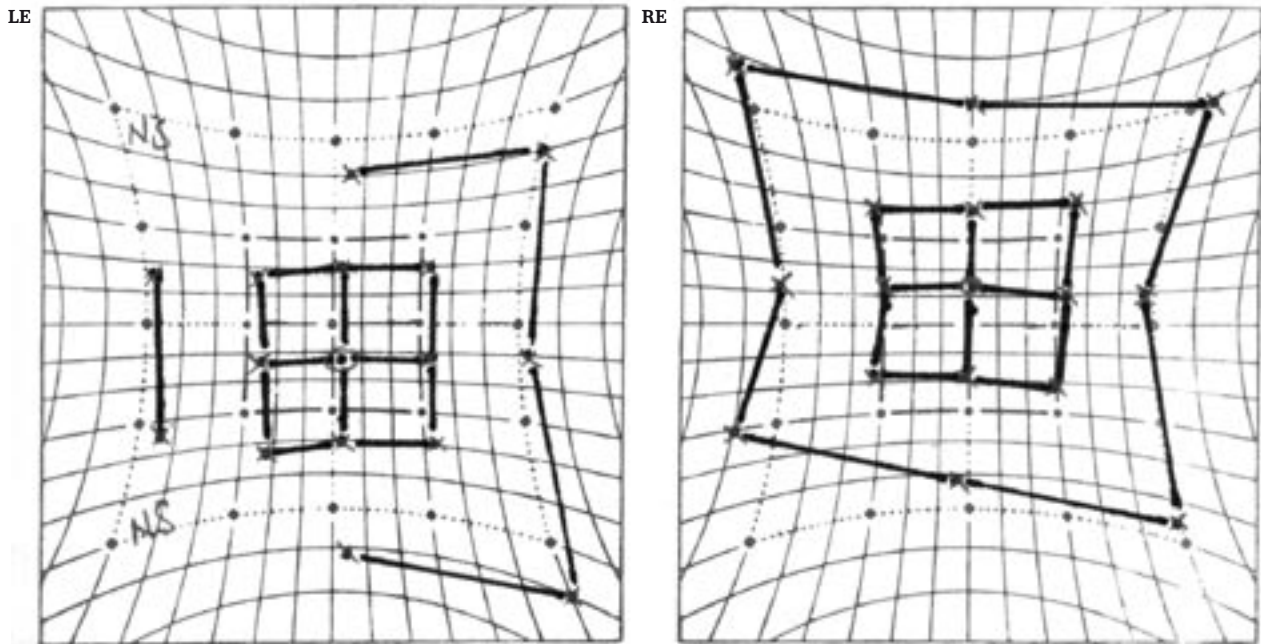


Figure 1. Hess Chart pre ice test

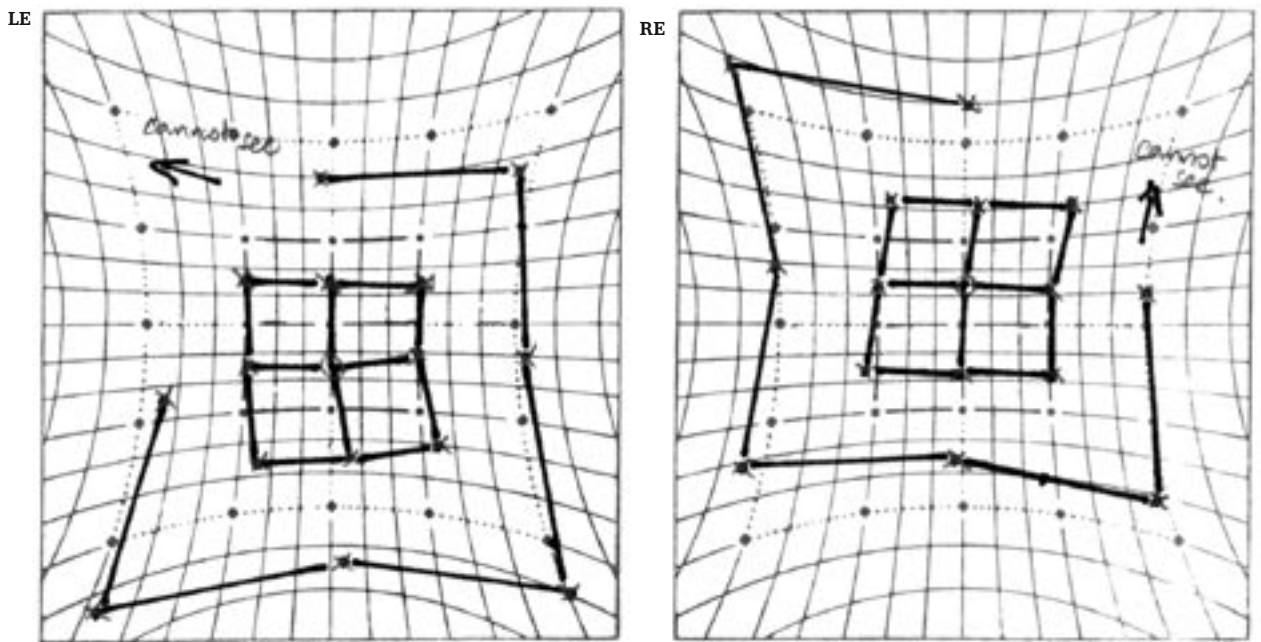


Figure 2. Hess Chart post ice test

required during the winter months or when working in his air-conditioned workshop during the summer months.

Visual acuity was 6/4 in both eyes with  $-0.25$  DS, with normal pupil and funduscopy examinations. A right superior oblique palsy measuring eight prism diopters (PD) in primary position, increasing to 14PD in left gaze was present and

confirmed by the Hess chart. The Bielschowsky Head Tilt Test result was positive for a right superior oblique palsy.

Due to the extensive investigation in the past, normal funduscopy and the fact that the abnormality was confined to the ocular muscles no further investigations were conducted. An additional 3PD Fresnel was added to the 2PD

already incorporated in the distance and reading glasses. This alleviated the diplopia and the need for an increased CHP. On follow up visits the patient reported the prismatic correction was required less frequently during autumn and not at all in the winter.

In the following summer, the patient returned complaining of a one week history of constant diplopia, which was present with and without the prismatic correction. The patient again reported that the increase in diplopia was associated with rising temperature. In an attempt to alleviate the diplopia the patient wore his near and distance prismatic correction simultaneously. This provided a correction of 10PD, which was an increase of 5PD since the previous summer.

Ocular examination remained unchanged apart from the persistence of the right superior oblique palsy. The deviation had significantly increased over the 12-month period, which was evident on the Hess chart.

The possibility of increased temperature as a dissociating factor in superior oblique palsies was not an aetiology we had encountered. However, the patient's persistent history of an increased deviation associated with increased ambient temperature, created suspicion of a reaction similar to "Uhthoff's phenomenon".

A review of the literature revealed several studies demonstrating that increases and decreases in temperature can affect nerve conduction in muscles and can have profound effects in neuromuscular conditions such as myasthenia gravis (MG).<sup>7-9</sup> The physiological mechanism underlying this reaction is that increased temperature has a detrimental effect on neuromuscular transmission and muscle force generation.<sup>10</sup> Whereas lowering the temperature produces improvement in myasthenic muscle function, perhaps by inhibiting acetylcholinesterase function.<sup>11</sup>

Orbital cooling using the 'Ice Test' is an easily administered aid to differential diagnosis in OMG.<sup>10-17</sup> The ice test was introduced in 1979 as a simple office test for differential diagnosis of blepharoptosis in suspected OMG.<sup>12</sup> Although initially introduced for cases of blepharoptosis in OMG, since then several authors have used the test in aiding diagnosis of OMG in suspected ocular motility disorders.<sup>11-14</sup>

An ice pack wrapped in a towel was applied to the patient's right eye for a period of five minutes. On removal, the deviation in the primary position had decreased by 1 PD for distance and 2 PD for near. The Hess following the ice test showed a 10 PD recovery in the field of action of the right superior oblique compared to the pre ice test Hess (Fig 1 and 2). Subjectively, the patient reported a significant improvement in his diplopia, which was maintained for the remainder of the clinical visit.

The improvement in the Hess chart, the decrease in the deviation and the resolution of diplopia in primary position was interpreted as a positive result to the ice test. The

patient was referred to a neurologist for investigations of OMG. Results of the acetylcholine receptor antibody assay and single fibre electromyography (SFEMG) of both limb and orbicularis oculi were negative.

As a result of the negative findings the suspected aetiology of OMG was excluded and the patient was diagnosed with acquired idiopathic fourth nerve palsy. The patient has since had a right inferior oblique myectomy, and is now diplopia free post operatively and has remained so for 18 months and through two summers.

## DISCUSSION

The results of the OMG investigations in this case were negative, with the patient's ocular alignment restored with surgery. At present the patient remains symptom free. However, is the exclusion of a diagnosis of OMG an example of false negative response to specific OMG testing, particularly in the presence of a positive response to the ice test?

The literature highlights that the presence of negative responses to OMG investigative tests does not rule out the diagnosis of OMG.<sup>13</sup> Verifying the diagnosis of MG can be difficult as the diagnostic tests are not 100% sensitive or specific.<sup>10</sup> Furthermore, it is recognised that one-third of patients improve spontaneously in the early stages of the disease.<sup>19</sup> Many authors confirm that although SFEMG is considered to be the "gold standard" for diagnosis of MG, the test is known to have high false negative rates in OMG.<sup>10,13,17-19</sup> The results of SFEMG are reported to be positive in 91-100% of patients with generalized MG and can vary from 63% -92% of patients with OMG.<sup>10,17,18</sup> The possibility of a positive response in OMG increases significantly when the orbicularis oculi is tested rather than a limb muscle.<sup>10,13,17,19</sup>

In addition, ACh receptor antibodies are variably elevated in MG and may not be abnormal in 30-65% of patients with OMG.<sup>10,13,19</sup> The significance of this result is illustrated by Ellis et al<sup>13</sup>, who reported that if they had relied on the SFEMG test alone, "the true diagnosis of OMG would have been missed in 10 out of 14 patients" in their series. Of particular clinical significance in Ellis et al's study, where the ice test was used in conjunction with other diagnostic tests for OMG, all patients who had a positive response to the ice test had OMG. No patient with OMG had a false positive or paradoxical response to the ice test. In addition, none of the participants in the control group had a positive motility or blepharoptosis response to orbital cooling.<sup>13</sup> This positive response to the ice test is further supported by several other studies.<sup>10,16,17,20</sup>

If our patient did not have OMG how or why did he react to the ice test? Could sensitivity to temperature change be a previously unreported decompensation factor in superior oblique nerve palsies? No similar case study describing changes in ambient temperature as a contributing factor in

the decompensation of superior obliques palsy is reported in the literature. However, Larner and Thomas describe a patient with an isolated superior rectus palsy who had a negative response to the extensive OMG investigations but 'cooling' was observed to clearly have "a marked subjective and objective (Hess chart) effect on eye movements." Larner and Thomas suggested "that the underlying superior rectus underaction was due to MG (certainly very focal and unilateral presentations of MG do occur, albeit rarely) but subsequent investigations and treatment provided no evidence to support this diagnosis."<sup>14</sup>

Irrespective of this grey area, we have incorporated the ice test as an additional diagnostic tool in suspected cases of OMG with positive results. The use of the ice test in the diagnosis of OMG is a proven inexpensive, safe and easily administered diagnostic test, which has a high sensitivity and specificity and is a valuable adjunct to the invasive tests.<sup>13,15,20</sup>

Finally, the patient's accurate report of the impact of temperature changes to his symptoms and deviation should encourage us to include questions relating to temperature in history-taking. Indeed, a study of the patterns of decompensation in ocular muscle palsies compared to the time of year may be an interesting future study.

## REFERENCES

- Rosenbaum AL, Santiago AP. Management of selected forms of neurogenic strabismus. In: Rosenbaum AL, Santiago AP, editors. *Clinical Strabismus Management: Principles and Surgical Techniques*. Philadelphia: W.D. Saunders Company, 1999:219-223.
- von Noorden GK. Special Forms of Strabismus. In: von Noorden, editor. *Binocular Vision and Ocular Motility: Theory and Management of Strabismus*. 5th edition. St. Louis: Mosby, 1996:411-412.
- von Noorden GK, Murray E, Wong SY. Superior oblique paralysis. A review of 270 cases. *Arch of Ophthalmol* 1986;104:1771.
- Rush JA, Shaffrin F. Ocular myasthenia presenting as superior oblique weakness. *J Clin Neuroophthalmol* 1982;2:125-127.
- Gunderson CA, Mazow ML & Avilla CW. Epidemiology of CNIV palsies. *Am Orthopt J* 2001;51:99-102.
- Kanski JJ. *Neuro-ophthalmology* In: Kanski JJ, editor. *Clinical Ophthalmology*. 2nd ed. London: Butterworth-Heinemann Ltd, 1990:444.
- Borenstein S, Desmedt JE. Temperature and weather correlates of myasthenic fatigue. *Lancet* 1974;13:63-66.
- Borenstein S, Desmedt JE. Local cooling in myasthenia. *Arch Neurol* 1975;32:152-157.
- Rutkove SB. Effects of temperature on neuromuscular electrophysiology. *Muscle Nerve* 2001;24:867-882.
- Golnik KC, Pena R, Lee AG, Eggenberder ER. An Ice Test for the diagnosis of Myasthenia Gravis. *Ophthalmology* 1999;106:1282-1286.
- Sethi KD, Rivner MH, Swift TR. Ice pack test for myasthenia gravis. *Neurology* 1987;37:1383-1385.
- Saavedra J, Femminini R, Kochen S, deZarate JC. A cold test for myasthenia gravis [letter] *Neurology* 1979;29:1075.
- Ellis FD, Hoyt CS, Ellis FJ, Jeffery AR, Sondhi N. Extraocular muscle responses to orbital cooling (Ice Test) for ocular myasthenia gravis diagnosis. *J AAPOS* 2000;4:271-281.
- Larner AJ, Thomas DJ. Can myasthenia gravis be diagnosed with the ice pack test? A cautionary note. *Postgrad Med J* 2000;76:162-163.
- Miller NR. The office diagnosis of myasthenia gravis. *Am Orthopt J* 2000;50:64-75.
- Movaghar M, Slavin ML. Effect of local heat versus ice on blepharoptosis resulting from ocular myasthenia. *Ophthalmology* 2000;107:2209-2214.
- Kubis KC, Danesh-Meyer HV, Savino PJ, Sergott RC. The ice test versus the rest test in myasthenia gravis. *Ophthalmology* 2000;107:1995-1998.
- Barton JJ, Foulavand M. Ocular aspects of myasthenia gravis. *Semin in Neurol* 2000;20:7-20.
- Howard JF. Myasthenia gravis: A summary. <http://www.myasthenia.org/information/summary.htm> November 1997
- Lertchauanakul A, Gamnerdsiri P, Hirunwiwatkul P. Ice test for ocular myasthenia gravis. *J Med Assoc Thai* 2001;1(Suppl):5131-5136