

## Acquired Colour Vision Assessment – Is Ishihara Really Enough?

Kylie Green, BAppSci(Orth)

Orthoptic Department, Sydney Hospital & Sydney Eye Hospital, Sydney, Australia

### ABSTRACT

**Purpose:** A quality improvement project was conducted to determine the most appropriate colour vision test for investigating acquired colour vision loss. The Ishihara Pseudoisochromatic Plate Test (Ishihara) is commonly used in many clinical settings for detecting acquired colour vision defects. However, the Ishihara is a screening test specifically designed to detect congenital red-green colour vision defects. While optic nerve pathology often causes red-green defects, this is not the same as a congenital loss. There is a strong need for in depth colour vision testing to be routinely utilised in clinical settings as colour loss is often the first sign of pathology.

**Method:** Thirty patients aged 23-76 with suspected optic nerve or macula pathology who were referred to the orthoptic department for colour vision testing, were assessed with the Farnsworth-Munsell 100 Hue (FM 100), Roth 28 Hue (Roth 28) and the Ishihara. The results of these three tests were compared. A control group consisting of 10 patients with no identified pathology were also tested with the FM 100 to ascertain if reliable results can be achieved despite the length of the test.

**Results:** Of the thirty patients, only one patient had a defect on the Ishihara. The Roth 28 did detect some losses, however, the defects were minimal and not clustered thus the abnormality could not be classified or monitored. The FM100 detected significant changes or abnormalities in colour vision in half of the 30 patients. The 10 control subjects all fell within the high to normal colour discrimination range on the FM 100 hue, with no abnormal axial patterns reported. The significance of these findings is demonstrated by three case studies, which outline the necessity of utilising the FM 100.

**Conclusion:** The comparison of all three tests shows that the Ishihara is not sensitive enough to detect acquired colour loss and is a poor substitute. While the Roth 28 does detect some colour changes it does not show enough detail to be a useful diagnostic tool. Colour vision testing is a key diagnostic tool and the correct test should be utilised in all clinical settings to aid diagnosis and to monitor progression or regression of optic nerve and macula pathologies.

**Key words:** colour vision, Ishihara, Farnsworth-Munsell, optic nerve pathology, acquired colour defects, Roth 28 hue.

### INTRODUCTION

Colour vision defects can be acquired and may be among the earliest symptoms of ocular damage from disease or toxicity.<sup>1</sup> It is vital to accurately identify and quantify colour vision changes as this can lead to early diagnosis and also identify changes in disease status.

While most clinicians do consider colour vision when assessing patients with suspected optic nerve or macula pathology, many solely rely on the Ishihara, which is quick and easy to administer.<sup>3</sup> However, the Ishihara was designed to detect congenital red-green abnormalities, "acquired

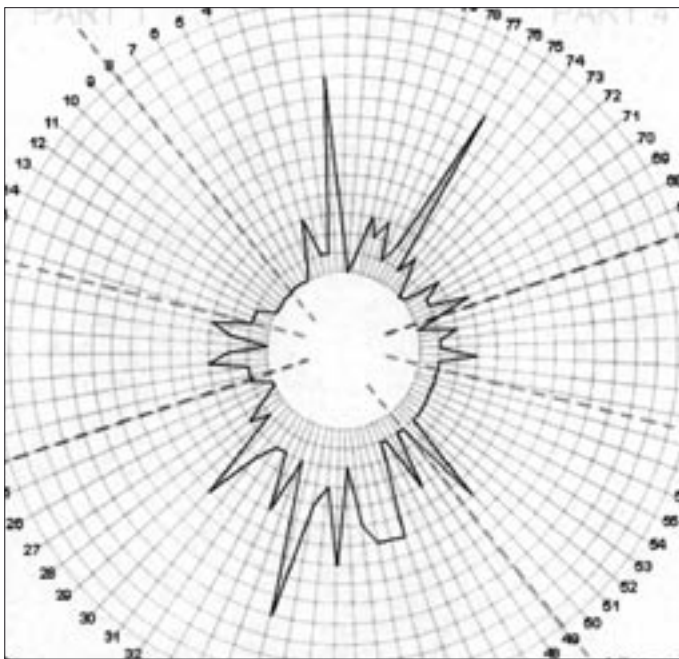
abnormalities were not taken into consideration in designing the test".<sup>2</sup> The Ishihara distinguishes normal colour vision from congenital colour vision defects, however, it does not evaluate the colour discrimination abilities of those with normal colour vision.<sup>1</sup> It is therefore inappropriate to use this test when testing patients with suspected acquired abnormalities.

Tests that are designed to detect congenital abnormalities fail to accurately detect acquired colour loss because of the different mechanisms involved in causing each abnormality.<sup>1</sup> Congenital loss is most commonly red-green but can be blue-yellow and is caused by either a missing cone pigment or cones with abnormal absorption.<sup>1,2</sup> Acquired loss, on the other hand, occurs due to changes in pre-receptor filters such as lens opacities, selective damage to specific cone classes or disruption to post-receptor processing.<sup>1,3</sup>

Correspondence: **Kylie Green**  
Orthoptic Department, Sydney Hospital & Sydney Eye Hospital,  
8 Macquarie Street, Sydney, NSW 2000, Australia.  
Email: [Kylie.Green@sesiahs.health.nsw.gov.au](mailto:Kylie.Green@sesiahs.health.nsw.gov.au)

**Table 1.** Verriest's Classification of Acquired Colour Vision Abnormalities

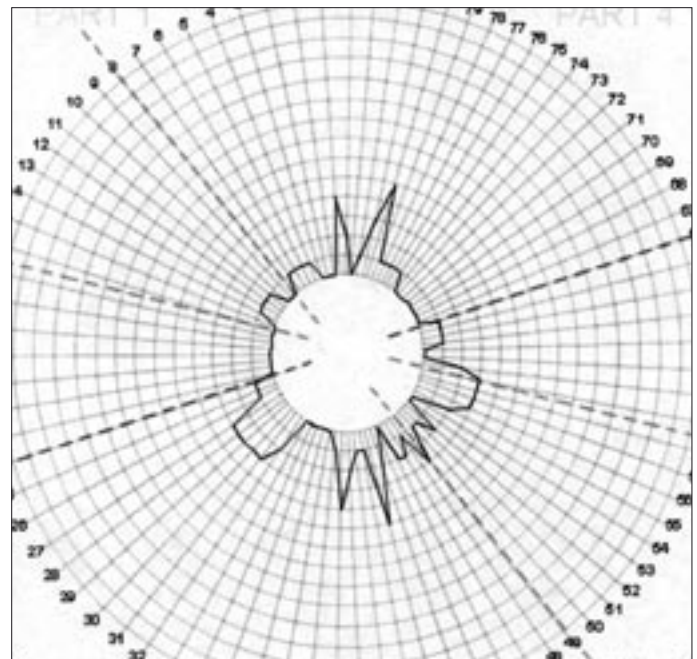
	Visual Acuity	Red-green Loss	Blue-yellow Loss	Typical Pathology
<b>Type 1 (Protan-like)</b>	Moderate to severe loss	Mild to severe loss	Little or no loss	Early destruction of foveal function with poor VA and central scotoma
<b>Type 2 (Deutan-like)</b>	Moderate reduction	Mild to severe loss	Mild loss	Optic nerve disease if VA affected
<b>Type 3 (Tritan-like)</b>	Normal to moderate loss	Less impairment than blue-yellow	Mild to moderate loss which is greater than the red green loss	Optic nerve and macular pathology where VA is preserved



a)

**Figure 1.** FM 100 left eye

a) On Ethambutol TES= 342 b) After ceasing Ethambutol TES = 266



b)

Many clinicians often follow the principles of Kollner's rule which states that "patients with retinal disease develop blue-yellow discrimination loss, whereas optic nerve disease causes red-green discrimination loss".<sup>3</sup> However, it is now known that outer retinal damage can also cause red-green defects and that blue defects can result from optic nerve pathology, as in early glaucoma where blue-yellow discrimination loss is often noticed in the early stages of pathology.<sup>1,3</sup> This is likely to be due to size and concentration of blue-yellow sensitive ganglion cells. As stated by Pacheco, Sahraie and Edgar<sup>3</sup>, blue-yellow sensitive ganglion cells or their axons have greater receptive fields, are larger than red-green cells and have a unique morphology and connectivity to second order neurons. Therefore, due to the anatomy of these cells if one blue-yellow coded ganglion cell is damaged there is a more dramatic effect on colour discrimination than if one red-green ganglion cell is damaged as there are "fewer ganglion cells which code blue-yellow signals and little overlap between receptive fields".<sup>3</sup>

Verriest reclassified acquired colour abnormalities into three categories, which relate the type of acquired loss to the retinal distribution of ganglion cells in the area of pathology<sup>3</sup>. Table 1 describes the fundamental principles of Verriest's classification. This classification highlights that when visual acuity is preserved (early stages of pathology) blue-yellow defects occur. It is only when the disease progresses and visual acuity is affected that red-green defects do also occur. This classification also highlights that acquired colour defects are often mixed affecting both red-green and blue-yellow discrimination.

The Ishihara may detect the red-green defects of advanced colour vision anomalies, however, when the colour abnormality has progressed to this stage the patient may not have the level of visual acuity necessary, as best corrected vision of 6/18 is required to accurately resolve the test.<sup>3</sup> Furthermore, the Ishihara is likely to miss the majority of early abnormalities, which only involve blue-yellow defects, as the test does not contain designs for the

detection of tritan defects. While this test is able to "isolate certain factors of colour deficiency it does not measure general colour discrimination"<sup>4</sup> and is therefore also unable to quantify the severity of this loss.

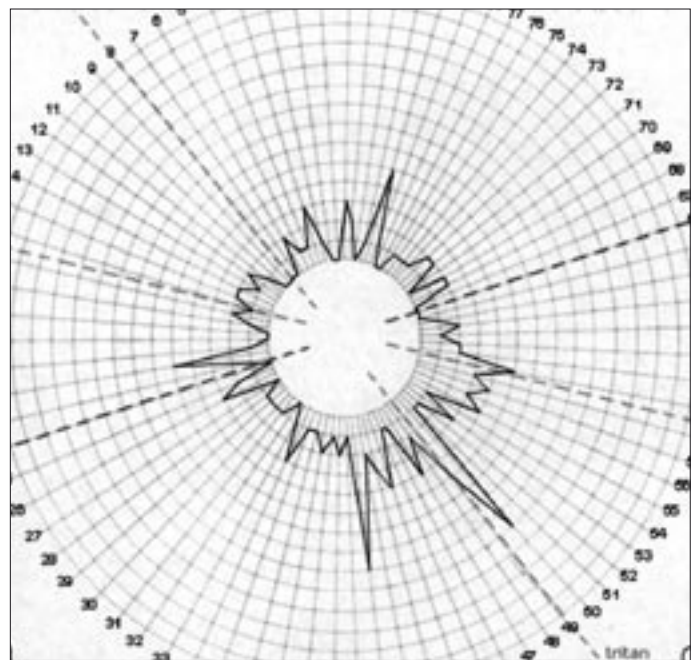
A more appropriate and sensitive test for detecting acquired colour vision abnormalities is the FM 100.1.<sup>5</sup> As stated by Farnsworth, this test was designed to separate persons with normal colour vision into classes of superior, normal and low colour discrimination and to measure the zones of confusion in patients with defective colour vision.<sup>6</sup> While this test is more time consuming than the Ishihara, it provides a more thorough evaluation. The FM 100 is able to both classify the colour abnormality by graph formation and provide a quantitative evaluation by means of the Total Error Score (TES), which allows changes in the abnormality to be monitored.<sup>3,5</sup> Although the FM 100 is particularly useful in monitoring progression in acquired deficiency, it is unable to distinguish subtle differences, such as between severe trichromatic anomalies and pure dichromacy. This can only be determined with the Nagel Anomaloscope.<sup>3</sup>

Another clinical test used for detecting acquired colour vision defects is the Roth 28. This is effective in detecting several severe acquired abnormalities however, it may not be sensitive enough to detect subtle defects, which could predict the onset, severity or progression of pathology. Furthermore, the Roth 28 does not give an exact score making it difficult to monitor subtle changes.<sup>5</sup>

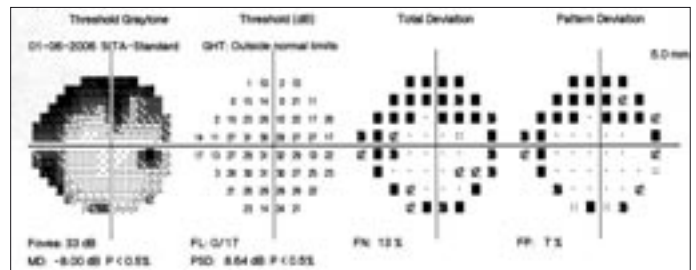
Having identified from the literature, possible shortfalls of the most commonly used colour vision tests and the physiology of acquired colour vision abnormalities, we conducted a quality improvement project to compare colour vision tests and evaluate the appropriateness of these tests in assessing acquired colour vision abnormalities. This paper presents these results of this study with particular emphasis on several cases to highlight the clinical differences between the tests.

## METHOD

Ethics approval was gained to conduct a quality improvement project to ensure the Orthoptic Department at Sydney Eye Hospital utilises the most appropriate colour vision test when investigating acquired colour vision defects. The study consisted of all patients referred to the orthoptic clinic over a six month period for colour vision assessment due to suspected or diagnosed optic nerve or macular pathologies in the presence of no other documented ocular pathology. Patients with other ocular pathologies were excluded. There were a total of 30 patients, aged 23-76 with an mean age of 46 years. Best corrected visual acuity, fundus examination and Humphrey Visual Field tests were performed with additional tests such as contrast sensitivity and radiological imaging carried out when appropriate. An ophthalmologist assessed all patients.



**Figure 2.** a) Pre Steroid Treatment right eye  
a) RE FM 100 Hue TES = 314 b) RE Humphrey Visual Field Test



The purpose of colour vision assessment was to either identify the severity of the pathology or assist in confirming its presence. Colour vision was assessed using the Ishihara, Roth 28 and FM 100. Each eye was tested separately with near correction and the assistance of a blue daylight globe to give optimal and even illumination. The order of the tests was randomised and all tests were performed at the one visit. Of the 30 patients, 24 had both their eyes tested, whilst for 6 patients only one eye was tested due to existing pathology of the fellow eye. In total 54 eyes were assessed.

The 24-plate edition of the Ishihara test was used with the patient given three seconds to respond to each page as suggested in the instruction manual.<sup>2</sup> Plates one to fifteen were tested and, as stated in the manual, colour vision was considered to be normal if thirteen or more plates were read correctly.<sup>2</sup>

When performing the Roth 28 and FM 100 the patients were given an unlimited amount of time to complete the test and an opportunity to review placement and make any changes. The patients were instructed in the correct handling of the colour chips and supervised at all times to ensure the test

**Table 2.** Individual Patient Results

Patient ID	Age	Pathology	Corrected VA	Ishihara	Roth 28	FM 100
1	43	Optic Neuritis	R 6/7.5 L 6/6	15/15 RGL	No errors	Score = 286 Score = 318
2	76	Glaucoma	R 6/7.5 L 6/6	15/15 RGL	No errors	Score = 298 Score = 318
3	69	TED	R 6/12- L 6/6	15/15 RGL	R no errors, L 3 cap reversals	Score = 266 Score = 258
4	42	TED	R 6/6	15/15 RE	No errors	Score = 214
5	30	Optic Neuritis	R 6/9 L 6/12	15/15 RGL	No errors	Score = 234 Score = 218
6	66	Empty Sella Syndrome	R 6/7.5 L 6/6	15/15 RGL	R No errors, L 1 cap reversal	Score = 314 Score = 310
7	39	Optic Neuritis	R 6/6 L 6/9	15/15 RGL	R 2 reversals, L 2 reversal 1 error	Score = 294 Score = 338
8	38	Optic Neuritis	R 6/6 L 6/6	15/15 RGL	R 3 reversals, L No errors	Score = 298 Score = 202
9	51	Optic Neuritis	R 6/6	15/15 RE	R 3 errors	Score = 238
10	63	Ethambutol	R 6/6 L 6/9	15/15 RGL	No errors	Score = 306 Score = 342
11	53	Plaquenil	R 6/7.5 L 6/6	15/15 RGL	No errors	Score = 210 Score = 226
12	47	TED	R 6/6 L 6/7.5	15/15 RGL	No errors	Score = 218 Score = 194
13	62	RP	R 6/15 L 6/21	15/15 RGL	No errors	Score = 230 Score = 206
14	48	TED	R 6/6 L 6/6	15/15 RGL	R G L 1 reversal	Score = 234 Score = 262
15	24	Optic Neuritis	R 6/6 L 6/15	15/15 RGL	No errors	Score = 198 Score = 446
16	32	R Optic Neuritis (severe)	L 6/5	15/15 LE	1 reversal	Score = 314
17	31	Optic Neuritis	R 6/6 L 6/6	15/15 RGL	No errors	Score = 258 Score = 266
18	57	TED	R 6/6 L 6/12	15/15 RGL	R 2 reversal, L 2 error 1 reversal	Score = 238 Score = 286
19	31	Papilledema	R 6/12 L 6/9	15/15 RGL	R 1 reversal, L 3 reversals	Score = 322 Score = 370
20	35	TED	R 6/6 L 6/6	15/15 RGL	R No errors, L 2 errors, 2 reversal	Score = 342 Score = 322
21	33	Optic Neuritis	R 6/12 L 6/30	15/15 RGL	No errors	Score = 238 Score = 274
22	56	TED	R 6/6 L 6/9	15/15 RGL	No errors	Score = 238 Score = 210
23	62	TED	R 6/5 L 6/6	15/15 RGL	No errors	Score = 194 Score = 210
24	64	R CRVO, L Optic Atrophy	R 6/7.5 L HM	R strong deutan	R Strong deutan	Score = 306
25	23	Optic Neuritis	R 6/6 L 6/5	15/15 RGL	No errors	Score = 226 Score = 226
26	59	TED G MG	R 6/9 L 6/6	15/15 RGL	1 reversal R G L	Score = 310 Score = 294
27	47	TED	R 6/6 L 6/12	15/15 RGL	R 2 reversals ,L 2 reversals	Score = 234 Score = 194
28	44	TED	L 6/4	15/15 RGL	No errors	Score = 250
29	40	TED	R 6/6 L 6/6	15/15 RGL	No errors	Score = 202 Score = 186
30	41	Optic Neuritis	R HM L 6/9	15/15 LE	L 2 reversals	Score = 314

TED = Thyroid Eye Disease, RP = Retinitis Pigmentosa, MG = Myasthenia Gravis, CRVO = Central Retinal Vein Occlusion

was being performed accurately.

The results of the Roth 28 were recorded by the examiner and plotted on the hue circle recording sheet. Colour vision was considered normal when the hue circle was a complete circle, or only minor errors or reversals occurred that were not clustered in the one area. The results were considered abnormal when the cap errors were clustered or created lines that crossed the hue circle.<sup>5</sup>

The results of the FM 100 were recorded by the examiner and calculated to obtain the hue circle and TES. A perfect score was considered to be 170, superior discrimination 171-186, normal discrimination 190-270 and low discrimination scores greater than 270.<sup>5,6</sup>

The results of each of the three tests were recorded on a

spreadsheet along with the patients' age, best corrected visual acuity and pathology or suspected pathology. The results of the three tests were compared to ascertain if the Ishihara is able to detect acquired colour vision loss, or should a more detailed colour vision assessment be carried out in patients with suspected or diagnosed pathology.

As the test duration and performance requirements have been identified as major drawbacks of the FM 100, 10 control subjects with no ocular pathology were randomly selected to undergo the test procedure.<sup>1,3,5</sup> The purpose of this was to evaluate if accurate results could be achieved on the first attempt, despite the length and difficulty of the test. The subjects in the control group were aged 20 - 55 with a mean age of 40. A hue circle and TES were formulated and recorded by the examiner on a spreadsheet.

## RESULTS

Of the 30 patients with pathology or suspected pathology 1 patient had an abnormal Ishihara result in one eye. All other patients scored within the normal range with the Ishihara in each eye tested.

The results of the Roth 28 showed 20 patients had no errors in one or both eyes. Twelve patients had errors in adjacent caps in one or both eyes. These errors were considered to be within normal given that "the simple transposition of chips represents minor errors which are only significant where there is accumulation or a particular distribution".<sup>7</sup> Five patients had errors in one or more eyes that showed clustered errors or errors that crossed the hue circle. The specific colour defect could be ascertained in only one patient who had a deutan-like abnormality. The other patients' errors did not lie on one specific axis, therefore, the type of colour abnormality could not be classified.

The results of the FM 100 showed 15 patients had superior to normal colour discrimination in one or both eyes. Three of these 15 patients had one eye assessed. The remaining 15 patients had low colour discrimination with abnormal hue circles in one eye or both eyes. Three of these patients had one eye only assessed.

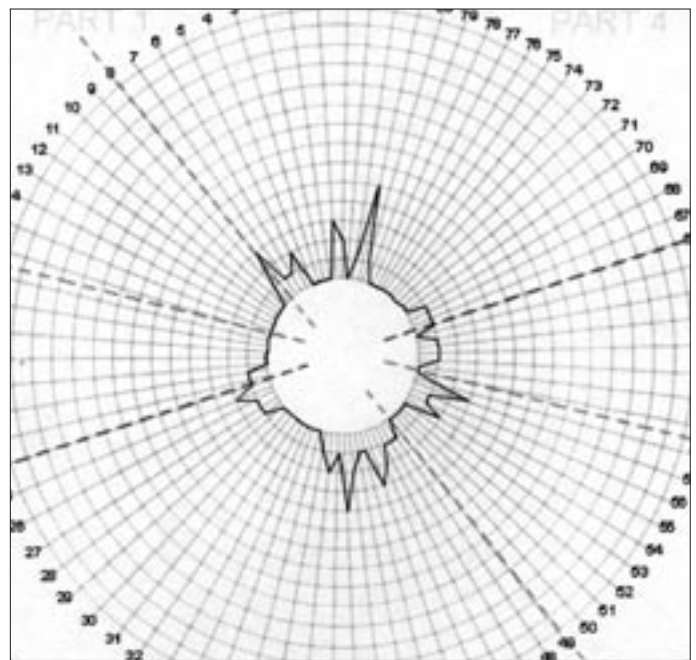
The 10 control patients were all able to achieve total error scores which fell in the superior or normal colour discrimination ranges, with normal hue circle patterns. These results do not imply there is no learning effect when performing the FM100, rather it highlights that this may not impact greatly on the final result.

The results showed that colour vision abnormalities were detected in 50% of the patients when using FM 100, while the Roth 28 detected 17% percent and the Ishihara only 3%. Therefore, if the Ishihara or Roth 28 had been used solely, a significant proportion of patients with acquired colour vision abnormalities would have been presumed to have normal colour vision.

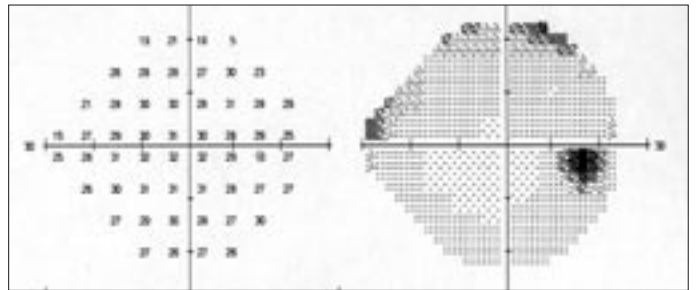
The following three cases have been selected to demonstrate how critical colour vision assessment is to patient management and highlight that Ishihara and Roth 28 are not sensitive enough in detecting what can be gross colour abnormalities.

### CASE 1

Mr L was diagnosed with respiratory tuberculosis in May 2006. His treatment included Isoniazid 300mg mane and Ethambutol 1000mg mane daily. He was referred to the orthoptic department for routine screening for optic nerve toxicity from Ethambutol. Testing revealed best corrected visual acuity of 6/9 right and 6/6 left, normal visual fields, normal contrast sensitivity with the CSV1000 and fundus examination by the ophthalmologist was unremarkable.

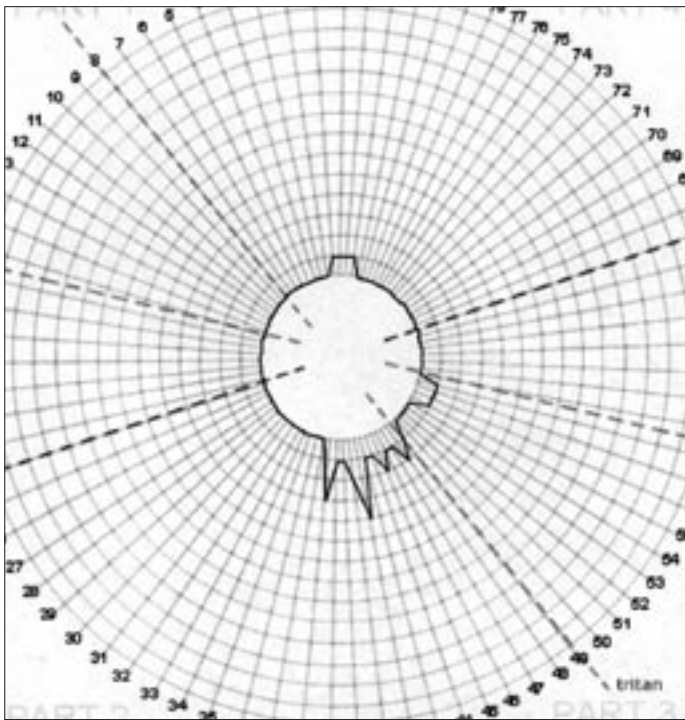


**Figure 3.**  
Post Steroid Treatment  
a) RE 100 Hue TES = 234 b) RE Humphrey Visual Field Test

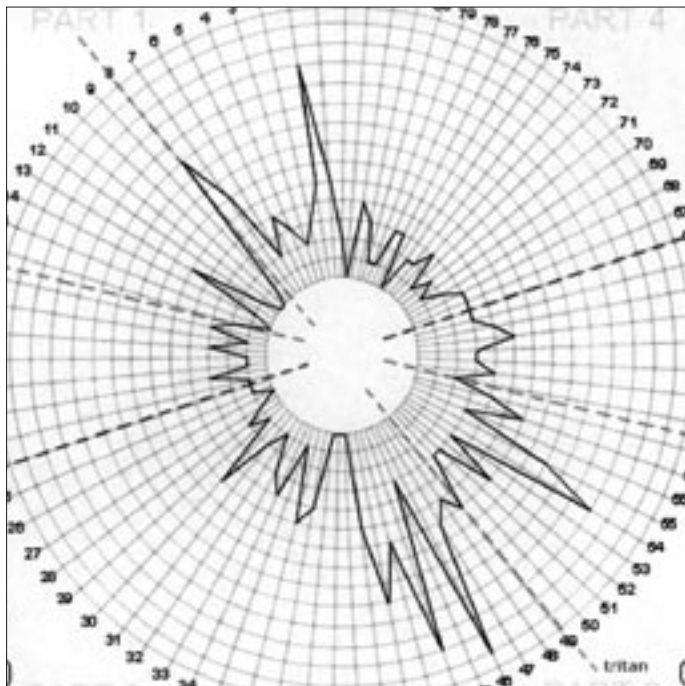


Colour vision testing was normal with the Ishihara and Roth 28, however the FM 100 showed gross tritan defects with TES of 362 in the right eye and 354 in the left. The FM 100 was repeated the following day and while there was a slight improvement, defects along the tritan axis were still present bilaterally. Ethambutol treatment was continued on the basis that all other tests were within normal limits and assessment was repeated four weeks later. At this visit fundus examination and Ishihara were normal and the Roth 28 was normal right and abnormal (tritan) left. The FM 100 showed gross tritan defects with TES of 306 in the right eye and 342 in the left eye.

Since commencing treatment, Mr L had also developed an itchy rash over his arms and lower body. Several treatments were tried throughout his admission but none could relieve the rash. It was then thought Mr L was having a reaction to the Ethambutol. A decision was made to discontinue Ethambutol based on this and his continued colour vision loss. The FM 100 hue was repeated four weeks later and improvement was seen. The right eye had improved to a TES of 286 and



a)



b)

**Figure 4.** Farnsworth Munsell 100 Hue  
a) RE TES = 198 b) LE TES = 446

the left eye to within normal with a TES of 266 (Fig 1).

### CASE 2

Mrs S was diagnosed with a left orbital pseudotumour in

April 2004, causing fibrosis of the inferior oblique and a left superior scotoma. She was treated with oral prednisone until February 2005. When the visual fields were retested in May 2006, there had been a marked deterioration, involving bilateral superior scotomas. Colour vision was tested and was normal right and left with the Ishihara, normal right and left with the Roth 28 and outside normal discrimination right and left with the FM 100 (Fig 2). The right eye had a TES of 314 and the left eye a TES of 310. In both eyes the hue circle showed a tritan-like defect. It was thought Mrs S may have compressive thyroid optic neuropathy, however, all blood tests disputed this. A diagnosis of empty sella syndrome was made and Mrs S commenced intravenous steroids initially then oral steroids. The diagnosis is still under review, however, with the steroid treatment both the fields and colour vision have improved (Fig 3).

### CASE 3

Mr M presented with a sudden onset of blurred left visual acuity with loss of peripheral visual field in the left eye. Visual acuity was 6/6 in the right eye and 6/15 in the left eye. He was referred to the orthoptic department for colour vision assessment due to suspected optic neuritis. The Ishihara and Roth 28 hue were normal in both eyes. The FM 100, however, showed a normal discrimination in the right eye with TES of 198 and grossly abnormal left eye discrimination with a score of 446 (Fig 4). Following treatment with oral prednisone Mr M's colour discrimination returned to within normal with a TES of 220.

### DISCUSSION

The above cases outline the importance of accurately measuring colour vision, as it can be a critical factor in diagnosis and management. In the case of Mr L, the colour vision assessment with the FM 100 detected optic nerve toxicity at initial investigation. However, as the visual fields were normal it was considered that toxicity was not present. The fact that Mr L's colour discrimination improved after Ethambutol was ceased demonstrates that colour vision is an accurate method of assessing optic nerve function and possible toxicity. The case of Mrs S outlines that the changes occurring in visual fields mirrored changes in colour discrimination making accurate colour vision assessment as important as visual field assessment.

The case of Mr M also clearly highlights the inadequacy of the Ishihara and Roth 28, as a severe acquired colour abnormality registered normal on these tests. As shown in the literature review, acquired and congenital colour vision defects are two separate conditions that require different tools of investigation. If Ishihara is the sole test used in the investigation of acquired colour loss, severe colour defects may not be detected at all. Although the Roth 28 was designed

to detect both congenital and acquired colour defects, the findings of this study suggest that it is not sensitive enough to be a useful diagnostic tool when assessing acquired colour vision. In addition, as no error score is given, it is difficult to monitor progression and as is highlighted in the first case, monitoring progression of colour discrimination can be significant to patient management.

While the FM100 can be time consuming, in reality only a small amount of patients seen in an ophthalmic clinic will need this test. If more time and care is given to assessing these patients it may lead to earlier diagnosis and an increased ability to track changes in the disease process. Colour vision is a vital assessment for patients with optic nerve or macular pathology and should be adequately investigated.

## CONCLUSION

The comparison of all three tests shows that the Ishihara is not sensitive enough to detect acquired colour loss and is a poor substitute. While the Roth 28 does detect some colour changes it does not show enough detail to be a useful diagnostic tool as compared to the FM 100. As a result of this quality improvement study, the orthoptic department

at Sydney Eye Hospital now routinely perform the FM 100 on all patients referred for colour vision assessment due to macular or optic nerve pathology.

## REFERENCES

1. Swanson W, Cohen J. Colour vision. *Ophthalmol Clin North Am* 2003;16:179-203.
2. Ishihara S. *The Series of Plates Designed as Tests for Colour Blindness: Instruction Manual*. Tokyo: Kanehara Shuppan Co., Ltd, 1939.
3. Pacheco M, Sahraie A, Edgar D. Acquired colour vision defects in glaucoma: their detection and clinical significance. *Br J Ophthalmol* 1999;83:1396-1402.
4. Bayer A, Thiel H, Zrenner E, et al. Colour vision tests for early detection of antiepileptic drug toxicity. *Neurology* 1997;48:1394-1397.
5. Fitzgerald A. A review of the Farnsworth Munsell type colour vision tests. *Aust Orthopt J* 1991;27:25-36.
6. Farnsworth D. *The Farnsworth-Munsell 100 Hue Test for the Examination of Color Discrimination: Instruction Manual*. Paris: Luneau Ophthalmologie, 1976.
7. Roth A. *The Roth 28 Hue Test according to Farnsworth-Munsell: Instruction Manual*. Paris: Luneau Ophthalmologie, (undated).