

A Case of Diplopia Following Monovision with Contact Lenses

Barbara Haynes, DOBA PGDipHlthResMeth

Department and Clinical School of Orthoptics, Royal Victorian Eye & Ear Hospital, Melbourne, Australia

ABSTRACT

A 46-year old woman presented with a 12-month history of diplopia after being prescribed monovision contact lenses. The iatrogenic anisometropia caused decompensation of

an esophoria, resulting in diplopia. A normal binocular state was reinstated with glasses, but it was necessary to incorporate prisms to achieve single vision.

Keywords: diplopia, monovision, contact lens

INTRODUCTION

In the era of 'throw away your glasses', the early stages of presbyopia present a challenge for the patient and the eye care professional. The successful contact lens wearer may now be needing glasses for reading. The mid-forties patient considering refractive surgery should be advised that throwing away their distance glasses will mean wearing reading glasses. Monovision, where one eye is corrected for distance vision and the other corrected for reading vision, is becoming an increasingly popular method to overcome these problems.

However, not everyone can tolerate monovision, with limitations including the lack of an intermediate focal distance, visual discomfort caused by anisometropic blur and binocular disruption. Success rates have been reported between 59% and 67% using contact lenses in patients who have already adapted to contact lenses wear.^{1,2} A Sydney-based study offered monovision with contact lenses to 1,133 presbyopes who were not already contact lens wearers. Only 28% were interested in trying monovision, and only 6.4% were actually fitted with contact lenses. Only one-third of these were interested in continuing with monovision after a one-month trial period, meaning only 2.8% (n=32) of the original participants continued with contact lens wear.³ The success rates of surgically-induced monovision are reportedly higher, ranging from 73%⁴ to 96%.⁵ This could be due to the difficulty handling contact lenses, residual astigmatism or the constant optical correction of a permanent surgical procedure facilitating binocular adaptation.⁵

The literature on success rates highlights the key issue of patient selection.⁶ Certainly some occupations are not suitable for monovision. The airline pilot or professional driver should be steered away from this option due to the decrease in binocular vision and blur factor.

CASE REPORT

A 46-year old woman, Ms Y, presented to the Ocular Motility Department at the Royal Victorian Eye and Ear Hospital with diplopia for driving and television for the past 12 months. She was distressed by these symptoms and had undergone several consultations previously elsewhere.

Ms Y had no past history of strabismus or occlusion, had moderate myopia and anisometropia with a glasses prescription of -3.50DS and -5.00DS for the right and left eye respectively, and was a contact lens wearer. Monovision contact lenses had been prescribed, with the right eye used for distance and the left eye for near. Diplopia was noticed three months later.

Subjective refraction whilst wearing contact lenses showed 1.50DS of uncorrected anisometropia. Spectacle prescription was correct according to subjective refraction. No cycloplegic refraction was done. Ocular examination showed a constant left esotropia measuring 20PD for both near and distance with no diplopia in the clinical setting. Ocular movements were full indicating no paretic or restrictive element and, with her correct spectacle prescription, vision was 6/5 in each eye. At this point the differential diagnosis was between a childhood esotropia which had increased in size and moved out of a suppression scotoma, a decompensated esophoria, and an acquired esotropia which had occurred during the period of monovision wear.

Correspondence: **Barbara Haynes**
Department and Clinical School of Orthoptics, Royal Victorian Eye & Ear Hospital,
East Melbourne, VIC 3002, Australia
Email: Barbara.Haynes@eyeandear.org.au

Magnetic resonance imaging was normal, finding no suggestion of a recent onset deviation. Further orthoptic investigation showed normal binocular functions on the Synoptophore, with normal retinal correspondence and a negative fusional amplitude of two degrees and a positive fusional amplitude of seven degrees, giving a fusion range of nine degrees. Sbia bar gave diplopia from filter 2, showing a shallow suppression scotoma and, when the deviation was fully corrected with prisms, Worth Lights gave a binocular response. A diagnosis of decompensated esophoria was made. Presumably the iatrogenic anisometropia created by the monovision contact lenses had disrupted fusion and precipitated an esotropia.

Initial treatment was to stop monovision contact lenses and Ms Y resumed wearing her multifocal glasses. Her symptoms improved initially but diplopia was still very bothersome. A program of prism therapy was instigated. With a 20PD base-out Fresnel prism on the left lens a binocular response was achieved with Worth Lights. Any less prism showed left suppression. This prism was fitted and one month later the patient was symptom-free with glasses, but still diplopic without the prism. Over the next 10 months attempts were made to wean off the prism. As Ms Y was still suppressing in the clinical setting, binocularity could only be assessed using Worth Lights. Prisms were gradually reduced and a regime of physiological diplopia and stereogram exercises began. Prisms were reduced through 15PD, 12PD to 10PD, beyond which a binocular response on Worth Lights was not achieved. The patient continued to suppress in the clinical setting, the angle of deviation always remained the same and diplopia persisted without the prism in daily life.

Despite improving negative relative fusion to some degree, there remained a small, symptomatic manifest esotropia. Surgery was an option that Ms Y declined. She was very happy to be diplopia-free and finally the 10PD prism (5PD base-out each eye), was incorporated into her glasses. However, this outcome means contact lenses are no longer an option and Ms Y will need to permanently wear glasses with a prism.

DISCUSSION

It is unusual for contact lens monovision to precipitate an esotropia and diplopia. An extensive literature review on monovision by Evans⁶ found no cases of diplopia following monovision with contact lenses in patients without pre-existing strabismus. Only one paper presented three cases of fixation switch diplopia precipitated by monovision contact lenses. All these cases were adults with a pre-existing history of strabismus. In this instance, diplopia is elicited by forcing the strabismic eye to fixate. The suppression scotoma that is present in the strabismic eye may not be present in the dominant eye when the non-dominant eye is

fixing and so diplopia results.⁷

No cases of monovision contact lens wear causing an esotropia with diplopia could be found in the literature. However, this is not the case with monovision produced by refractive surgery. Schuler et al⁸ described a decompensated IVth nerve palsy with vertical diplopia after bilateral refractive surgery resulting in monovision. In this case the interrupted fusion caused decompensation of a previously controlled vertical deviation, with the patient finally needing glasses and a prism. Kushner and Kowal⁹ found five mechanisms to account for diplopia following refractive surgery; technical problems, prior need of prisms, aniseikonia, iatrogenic monovision and improper control of accommodation in patients with strabismus. Monovision was accountable for seven of the 28 patients with diplopia following refractive surgery, with three of these due to decompensated intermittent deviations, three due to fixation switch diplopia and one a decompensated IVth nerve paresis previously well controlled. The anisometropia produced in this group was between 1.50DS and 2.50DS. As with Schuler, this disruption to the binocular state decompensated a previously well controlled strabismus.

It has been shown that long-standing monovision in adults results in the absence of foveal fusion and reduced stereoacuity.¹⁰ Fawcett et al¹⁰ compared 32 adults with longstanding monovision (greater than six months) through refractive surgery with a control group. Even when the binocular state was restored with optical devices, patients in the monovision group showed reduced stereopsis on random dot stereo tests and suppression on Worth Lights, lending evidence to the view that the adult binocular visual system is susceptible to change throughout life. Indeed the success of monovision seems to depend on the adult patients' ability to learn to suppress the blurred image.

How can we identify which patients will be at risk from monovision? The American Academy of Ophthalmology guidelines for the management of refractive surgery suggest a pre-operative evaluation of ocular motility and alignment.¹¹ Kushner and Kowal⁹ go further, suggesting a trial of monovision contact lenses if there is more than a minimum of heterophoria, although this amount was not defined. However, it should be remembered that in our case it was three months before the monovision contact lenses produced symptoms of diplopia. It is unknown what, if any, ocular motility assessment was performed prior to giving monovision. It is also of interest that Ms Y was myopic with a convergent deviation.

Refractive surgery is a state not easily reversed. On the other hand, contact lenses can easily be removed and the binocular state restored. However, this case demonstrated that even the restitution of a normal binocular state may not be enough to restore a fusional amplitude sufficient for binocular single vision once it is disrupted. This finding is in agreement with Fawcett et al's conclusions that fusion

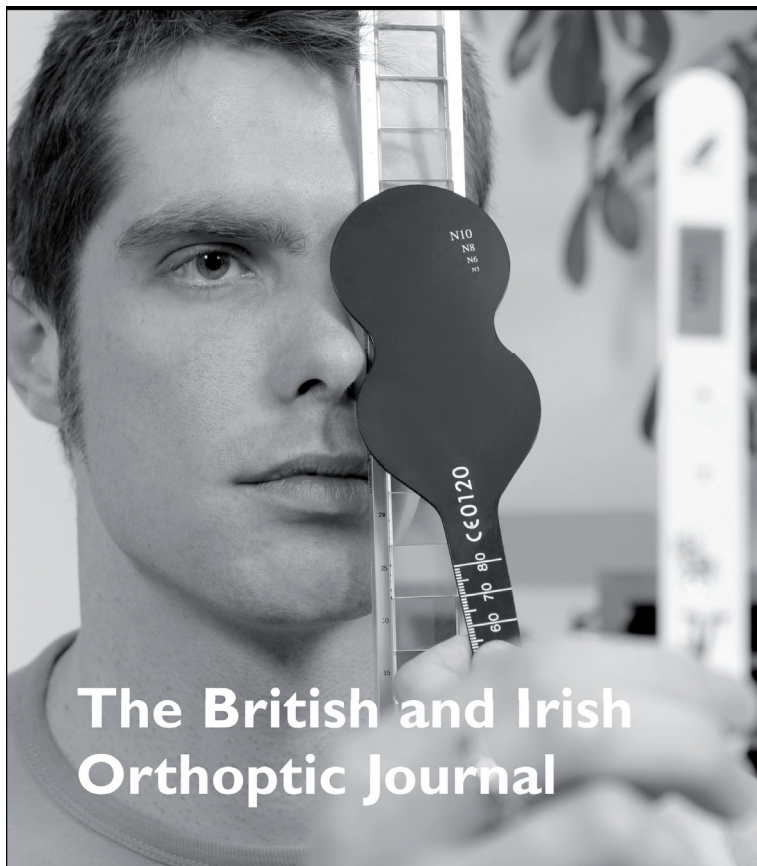
in adults can be lost if the visual system is disrupted.¹⁰ Ms Y had symptoms of diplopia for 12 months before coming to our clinic. In this time she had developed a shallow suppression scotoma which remained despite prism and orthoptic treatment. This suppression scotoma may well have impeded the full recovery of binocularity.

CONCLUSION

Diplopia caused by monovision use of contact lenses is an unusual occurrence. However, it is advisable to know the binocular state of each patient before prescribing monovision. A simple cover test is enough to elicit any significant heterophoria. In the case of significant heterophoria, the patient may be informed of the risks of monovision and advised not to proceed. Close supervision should follow if the patient chooses monovision despite advice.

REFERENCES

1. Du Toit R, Ferreira JT, Nel ZJ. Visual and nonvisual variables implicated in monovision wear. *Optom Vis Sci* 1998;75(2):119-125.
2. Erickson DB, Erickson P. Psychological factors and sex differences in acceptance of monovision. *Percept Mot Skills* 2000;91(3):1113-1119.
3. Gauthier CA, Holden BA, Grant T, Chong MS. Interest of presbyopes in contact lens correction and their success with monovision. *Optom Vis Sci* 1992;69(11):858-862.
4. Jain S, Arora I, Azar DT. Success of monovision in presbyopes: review of the literature and potential applications to refractive surgery. *Surv Ophthalmol* 1996;40(6):491-499.
5. Goldberg DB. Laser in situ keratomileusis monovision. *J Cataract Ref Surg* 2001;27(9):1449-1455.
6. Evans BJW. Monovision: a review. *Ophthalmic Physiol Opt* 2007;27(15):417-439.
7. Kushner BJ. Fixation switch diplopia. *Arch Ophthalmol* 1995;113(7):896-899.
8. Schuler E, Silverberg M, Beade P, Moadel K. Decompensated strabismus after laser in situ keratomileusis. *J Cataract Refract Surg* 1999;25(11):1552-1553.
9. Kushner BJ, Kowal L. Diplopia after refractive surgery: occurrence and prevention. *Arch Ophthalmol* 2003;121(3):315-321.
10. Fawcett SL, Herman WK, Alfieri CD, et al. Stereoacuity and foveal fusion in adults with long-standing surgical monovision. *J AAPOS* 2001;5(6):342-347.
11. American Academy of Ophthalmology Refractive Management/Intervention Panel. Guidelines: Refractive errors and refractive surgery. San Francisco: American Academy of Ophthalmology; 2007.



The British and Irish
Orthoptic Journal

The official annual publication of the British and Irish Orthoptic Society, the Journal contains papers covering orthoptics, ocular motility, amblyopia, binocular vision, strabismus, related paediatric ophthalmology and neuro-ophthalmology.

The editorial board comprises leading British and Irish orthoptists and ophthalmologists.

Original articles for publication may be submitted to the Editor:

Dr Sarah Shea PhD DBO(D), Orthoptic Clinic, North West Wales NHS Trust, Ysbyty Gwynedd, Bangor, North Wales LL57 2PW United Kingdom

